Bratisl Lek Listy 2010; 111 (3)
129 – 133

EXPERIMENTAL STUDY

The short term effects of infected gallstones lost intraperitoneally

Murat Ersen Bekar[1], Ali Erkan Ucar[1], Samet Yalcin[1], Bulent Yalcin[2], Ali Celik[1], Ahmet Kusdemir[1]

Department of General Surgery, Ankara Ataturk Research and Education Hospital, Bilkent-Yolu, Ankara 06800, Turkey.
sametyalcin71@yahoo.com

Abstract: In this experimental study, an animal model was set up to evaluate what sort of complications may cause intraperitoneal retained bile stones. Forty rats were divided into 4 groups. The first group was assigned as the control group and the subjects had only laparatomy. In the 2nd group, during laparotomy, sterile bile and bile stones were placed within the peritoneal cavity. In the 3rd group, contaminated bile and bile stones were placed within the peritoneal cavity. In the 4th group, again contaminated bile and bile stones were placed and prophylactic antibiotic (Ceftriaxon) was used for 7 days. After a 4 week interval, survivors were subjected to laparatomy and necropsy. As a conclusion, the peritoneal adhesion difference between the infected bile and stone inooculation group without antibiotic and the other group with antibiotic usage may show that antibiotics might prevent further complications in case of abdominal contamination. Available clinical and experimental data is not enough to recommend laparatomy to collect stones. We conclude that more detailed studies with larger series are necessary to clarify the issue *(Tab. 1, Fig. 1, Ref. 26)*. Full Text (Free, PDF) *www.bmj.sk.*
Key words: experimental study, intraperitoneal gallstone, laparoscopy.

Laparoscopic cholecystectomy has been largely replaced by open cholecystectomy in the management of symptomatic cholelitiasis recently (1–7). Laparoscopic cholecystectomy has the advantages of lower postoperative pain and shorter hospital stay, early restoration of physical activity and better cosmetic results. However, laparoscopic cholecystectomy brings some complications such as spill of the bile and gallstones and lose of gallstones in the intraperitoneal cavity as a result of the rupture of the gallbladder during the operation (2, 8–10). The perforation rate of the gallbladder is reported to be 13–20 %, and the lost of the gallstones in the abdominal cavity is reported to be 10–20 % in different series. Removal of the stones as much as possible and rinsing of the site with high volumes of isotonic saline are recommended when this complication occur, but sometimes all the stones could not be removed and many patients live with gallstones (2, 8).

Bile ascites or secondary peritonitis may result from the gall bladder perforation and spilling of bile through peritoneum during laparoscopic cholecystectomy. However, there are insufficient data about the effects and complications of intraperitoneally lost gallstones (2, 11).

An experimental study was performed in rats to evaluate the effects and resulting complications due to lost gallstones and spilling of bile during laparoscopic cholecystectomy. Previous studies reported results of experimental studies on infected bile and gallstones. However, none of these studies reported the effects of antibiotic prophylaxis following an intraperitoneal placement of infected bile and gallstones. This study also examined the effects of antibiotic prophylaxis on the intraabdominal adhesion formation caused by infected bile and gallstones.

Materials and methods

After the approval of the local ethic committee, 40 adult female rats (Rattus Norvegicus) weighing between 220–240 grams were used. After the anesthesia with ketamine (37.5 mg/kg) and xylozine (mg/kg, intramuscular), abdominal wall of all rats was shaved and rinsed with povidon iodide and laparotomy with 5–10 millimeters of median incision was performed. The rats were then divided to four groups. Group 1: control group (n=10), Group 2: sterile bile and gallstone placed group (n=10), Group 3: infected bile and gallstone placed group (n=10), Group 4: infected bile and gallstone placed and antibiotic prophylaxis group (n=10).

Touching with sterile surgical gauze to the right subhepatic area of the subjects in the group 1 was done after the laparotomy and 1 ml of sterile saline was applied. One milliliter of bile and a gallstone with 3 to 4 mm diameter was placed to the right subhepatic area of every subject in the group 2 under sterile settings. The bile and gallstone used in the group 2 have been acquired from the patient undergoing cholecystectomy due to asymptomatic chronic cholecystitis and sterility of the bile and gallstones have been documented by microbiologic examination.

One milliliter of bile and a gallstone with 3 to 4 mm diameter was placed to the right subhepatic area of every subject in the group 3. The bile and gallstone used in the group 3 was acquired from a patient undergoing cholecystectomy due to acute

[1]Department of General Surgery, Ankara Ataturk Research and Education Hospital, Bilkent-Yolu, Ankara, Turkey, and [2]Department of Internal Medicine, Ankara University School of Medicine, Sihhiye, Ankara, Turkey

Address for correspondence: Samet Yalcin, Dr, Ankara Ataturk Research and Education Hospital, Dept of General Surgery, Bilkent Yolu, TR-06800, Ankara, Turkey.
Phone: +90.312.2912525, Fax: +90.312.3192283

Tab. 1. Peritoneal adhesion grade scale by Nair.

Score	Finding
0	No adhesion formation
1	One omental band or thin, easily detachable adhesion formation
2	Two mental band or adhesion formation resistant to strain
3	Adhesion formation involving adjacent mesentry, bowel or other intraabdominal organs
4	adhesion of the internal organs to the abdominal wall directly

cholecystitis and E. coli and Enterococcus spp. have been documented by microbiologic examination.

The bile and gallstones in the group 4 were used in same way as in the group 3. However, the subjects in this group received intramuscular ceftriaxone, 30 mg/kg qd, during the postoperative period up to 7 days.

Incisions in all subjects in all groups have been closed in anatomic plane by using atraumatic polypropylene suture material after the procedures mentioned above. Rats have been fed with standard food and fresh vegetables and placed in an environment with steady temperature after the operation. None of the subjects in the group 1, 2 and 4 died, but 2 subjects in the group 3 died during the postoperative 2 weeks period. Laparotomy was performed in these 2 subjects and the changes in peritoneal cavity were examined. Samples were obtained from the peritoneum at the beginning of the laparotomy and from the lesions found during the laparotomy.

All the subjects in all groups were sacrificed by a high dose ether anesthesia in the fourth postoperative week, and underwent laparotomy. Peritoneal cultures were obtained at the beginning of the laparotomy and the lesions found during the laparotomy were evaluated macroscopically. Macroscopic findings were documented by photographs and adhesions found in abdomen were scored according to the adhesion grade scale developed by Nair (11) (Tab. 1).

All the cultures of the bile, gallstone and peritoneum specimens in this study have been performed in the microbiology department and all pathologic specimens were examined in the pathology department. Chi-square test was used for the statistical evaluation of the differences between groups.

Results

Peritoneal cultures; biopsies of liver, omentum and peritoneal biopsies, and adhesion scores of macroscopic adhesions were evaluated from all the subjects in the groups. All subjects in the group 1 lived for 4 weeks postoperatively. No bacterial growth was detected from the cultures from the peritoneal fluid obtained during the laparotomy at the forth week. Macroscopic adhesion was detected in 4 of the subjects, and all adhesion scores were 1 in all these subjects. There were no pathologic findings in liver, omentum and peritoneum biopsies (Fig. 1A).

No bacterial growth was detwctwd from the cultures from the peritoneal fluid obtained during the laparotomy at the forth week in subjects from the group 2. There was gallstone migration in 2 subjects. Gallstone was found in a peritoneal cyst located in upper pole of the right kidney in one of these subjects; and a free gallstone was found adjacent to small bowel in the other. There were macroscopic adhesions in 8 of the 10 subjects. Adhesion score was 3 in 5 of them and 2 in the remaining 3. There were no pathologic finding in any of the liver biopsies; however there were chronic inflammatory changes in omentum biopsies (Fig. 1B).

Two subjects in the group 3 died on postoperative day 5. There was a widespread peritonitis in laparotomy. Peritoneal fluid cultures revealed E. coli and P. mirabilis in both subjects. The gallstones were found in the right subhepatic area and there were no macroscopic adhesions and specific pathologic changes; but acute inflammatory changes have been found in the omentum biopsies from both subjects. There was no bacterial growth in the peritoneal fluids of other subjects obtained during the laparotomies performed on the forth week. There was a migration in three of the subjects. The gallstone was adhered to the anterior abdominal wall in omentum in one of these subjects; was adhered to the right inferior abdominal wall and enclosed by omentum in the second; and was adhered to right inferior pole of the kidney in the third. There were macroscopic adhesions in 7 of these subjects. The adhesion scores were 4 in three, 3 in two, and 1 in two of these subjects. There was no pathologic finding in any subject, but omentum biopsies of all subjects revealed a chronic significant inflammation in all subjects. There was a chronic pyelonephritis in one subject.

All the subjects in the group 4 underwent laparotomy in the week 4 and E. coli was detected from the peritoneal fluid cultures from 2 of these subjects. Gallstone was adhered to the anterior abdominal wall in one subject (Fig. 1C), was enclosed by omentum in one subject, was located in the perirenal fat tissue, and adhered to intestine meso in another subject. There was a macroscopical adhesion in 5 subjects. The scores of adhesion were 1, 2 and 4 in 1 subject, 3 subjects and 1 subject respectively.

No specific pathological finding was found in any subject's liver biopsy specimens. In addition, in omentum biopsy materials, chronic inflammation findings were less frequent than in the group 3 (Fig. 1D).

Discussion

As a result of laboratory experiments and clinical studies, laparoscopic cholecystectomy has replaced open cholecystectomy in the treatment of cholelithiasis, and has become the standard treatment method. However, unlike the open technique, there are two intraoperative complications frequently encountered in laparoscopic cholecystectomy. The first and most important one is the higher risk of the bile-duct injury when compared to the open surgery procedure, although it is rare (3, 6, 9, 10, 13–16).

The other complication, which is not widely considered, is the rupture of the bile duct or leakage of its contents into the abdominal cavity during dissection or manipulation. This minor

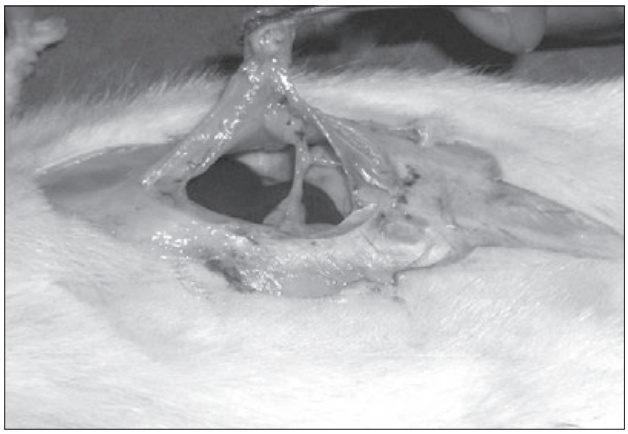

Fig. 1A. Adhesion on the incision line of the sterile bile and sterile gallstone used group in the form of single omental band.

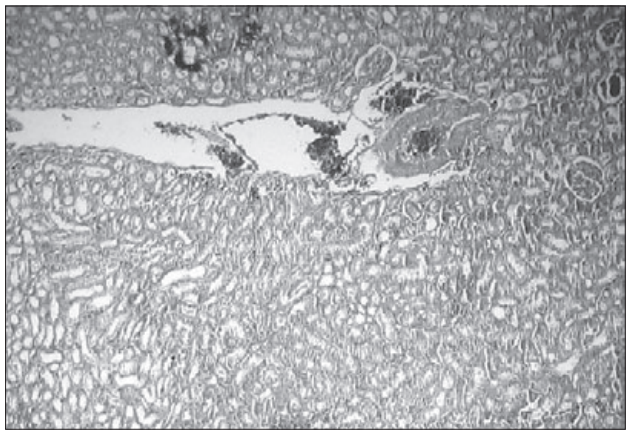

Fig. 1B. Pathological view of the omenthal specimen that is characterized with chronic inflammatory reaction which was taken from the group that was used sterile bile and sterile gall stone.

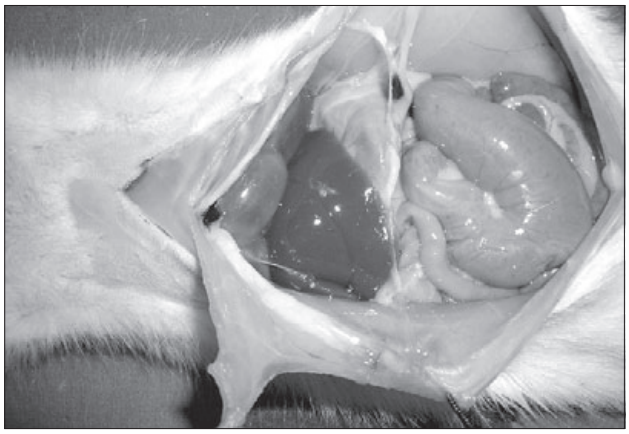

Fig. 1C. Migrated gall stone in the group prophylactic antibiotic was used after infected bile and infected gall stone were used.

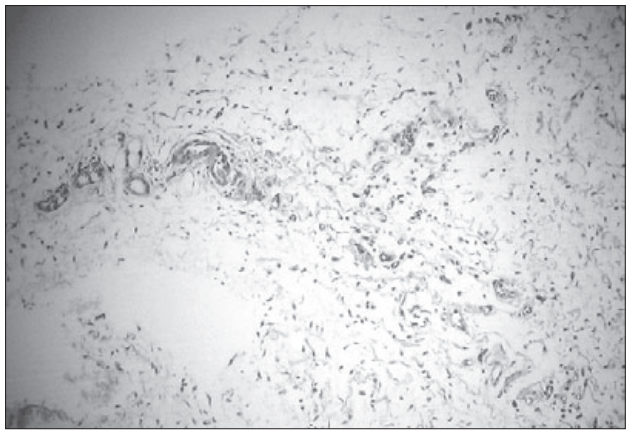

Fig. 1D. Although it was lower when compared to the group 3, pathological view of the chronic inflammation of the omenthal specimens of the group which prophylactic antibiotic therapy was used after infectes bile and infected gall stone were used.

event still occurs quite often (11). Ovaska and Havia could not retrieve gallstones from the abdomen of four out of 13 patients. A new surgical intervention was required in three of these patients on the first, seventh and thirty-first postoperative days, respectively. Billiary peritonitis developed in the first two patients (there was a hepatic duct erosion associated with gallstone in one of the cases) whereas epigastric wound infection developed in the third, which required surgical drainage (2, 8). Available experimental studies have demonstrated that small quantities of bile leakage alone are harmless. However, gallstones concomitant with bile leakage markedly increase adhesion formation and the risk of intra-abdominal abscess formation (2). Many researchers have indicated that large volumes of free bile leakages are the underlying cause of morbidity rates. On the other hand, various experimental studies have demonstrated that intraperitoneal injection of bacteria-containing bile in rats, at a concentration of $3x10^6$cfu/ml, may be lethal (26).

In an experimental study conducted at the Creighton University, the outcomes of gallstones were investigated. Human gallstones were collected under aseptic conditions and implanted in the peritoneum of New Zelland White rabbits; cholesterol and pigment stones were used in the experiment. By the second week, acute and chronic inflammation was observed around the implanted gallstone. Within two months, localized fibrosis and fatty necrosis was observed without any finding supporting a typical residual inflammation. There was no micro or macro abscess formation. Interestingly, about 25 % of pigment stone's volume loss was identified (8). Although the mechanism of this phenomenon is not well understood, intraperitoneal implantation of sterile human gallstones with a diameter of 5–7 mm was performed in 12 male rats during a study conducted by Harry C. Sax et al. The subjects were sacrificed and inspected 1, 2, and 4 months later. Although adhesions and volume of gallstones decreased in the first two groups, in the group examined 4 months later, not only there was an adhesion reduction, but there was also a complete disappearance of gallstones. This phenomenon was explained by the fact that rats, not having gallbladder, could absorb concentrated pigment stones (17).

In another experimental study, the effect of bile and gallstones scattered in the peritoneal cavity was studied. Sterile gallstones were placed in the peritoneum of rats, followed by intraperitoneal injection (2 mL) of physiological saline in Group 1, sterile bile in Group 2 and infected bile in Group 3. The resulting changes were analyzed (2). No reaction was observed in the group with injected physiological saline. On the other hand, intraperitoneal adhesion was observed in 70 % of the subjects in the groups with injected sterile and infected bile. Based on this data, it was concluded that the combination of intraperitoneal bile and gallstones increases the frequency of adhesion formation.

In the present study, an adhesion score of 1 was observed in four rats in the group 1 following laparotomy on the fourth week. These adhesions were easily separable and did not cause any complication. They were in the form of a single fibrotic band along the incision line in the abdomen, and the right upper intra-abdominal quadrant was clear due to injection of physiological saline. This was consistent with the experimental study conducted by Johnson et al (2).

Adhesion developed in eight rats in the group 2. Four of them had easily separable adhesions with a score of 2 whereas the other four had non-separable, dense adhesions with a score of 3. In a study conducted in Uludag University Faculty of Medicine by Zorluoglu et al, the formation of adhesions and the secondary increase in morbidity was not observed in the subjects in whom sterile bile and gallstone had been placed (11). In this group, migration developed in two of the subjects. One of them had a salistone free in the peritoneal cyst on the kidney's right upper pole. Pathologic examination of this kidney demonstrated no specific pathologic changes.

Pathologic examination of the liver omentum and peritoneum of all the subjects in this group demonstrated minimal chronic inflammatory changes in the biopsies of the omentum alone (8). In the group 3, two rats died on the post-operative fifth day due to extensive peritonitis and advanced inflammation. This condition is consistent with literature (2). Development of adhesion was observed in seven rats. The adhesions of this group were in the form of non-separable, dense, fibrotic adhesions that specifically attached to the surrounding tissue, with a score in between group 3 and 4. There was a significant difference from the adhesions of the group 2 ($p<0.05$). Qualitative difference between the group 2 and the group 3 may demonstrate that the developing adhesions following infection of the drained bile in the peritoneum and their complications may lead to more severe consequences (11, 12). Migration also appeared in three rats. In one of them, the gallstones were in the right upper pole of the kidney. Pathologic examination of this kidney revealed findings that were consistent with pyelonephritis. Comparison of these results with the conditions of the group 2 may suggest that the developing chronic pyelonephritis may be associated with infected gallstones.

Pathologic evaluation of the liver and peritoneum of all of these subjects revealed no specific changes. On the other hand, findings consistent with chronic inflammation were identified in the omentum biopsies of all patients. This difference between Group 2 and Group 3 may indicate a more complex foreign body reaction, which is accompanied by bacterial contamination (2, 3). Adhesions developed in five rats of group 4 that received infected gallstones, infected bile and antibiotic prophylaxis. They were easily separable, with an adhesion score of 2, identical to Group 2. Significant differences compared to Group 3 regarding the rate of adhesion development and adhesion score ($p<0.05$) may suggest that antibiotic treatment could be effective in reducing complications, which may arise in association with infected bile leakage and drained infected gallstone. In a study conducted by Johnson et al, no difference was identified between infected and sterile gallstones with regards to adhesion; however, it was reported that antibiotic prophylaxis may reduce the development of adhesions in conditions of drained infected gallstones (2, 11).

In the present experimental study, we have observed that antibiotic chemoprophylaxis of drained infected gallstones may qualitatively and quantitatively reduce adhesion formation. In 4 subjects of Group 4, migration developed in gallstones, which were placed intraperitoneally. In one of the subjects, gallstones were found in the perinephric adipose tissue. Pathologic examination of this kidney revealed findings that were consistent with chronic pyelonephritis, as in the subject of Group 3. However, the developing chronic pyelonephritis did not affect the kidney medulla and was bordered by the cortex. We are of the opinion that antibiotic prophylaxis administered in this group must have affected these results. No specific pathological finding was identified in the liver and peritoneal biopsies of all of these subjects in this group. On the other hand, in the omentum biopsy examination of all subjects, obtained findings were less consistent with chronic inflammation, compared to Group 3. We anticipated that antibiotic prophylaxis could be the reason for this condition, but no similar outcome was encountered in literature. As a result, it is suggested that extensive clinical and experimental sudies need to be conducted regardins this subject.

The suggestion that gallstones placed in the right upper intra-abdominal quadrant in all subjects of groups 2, 3 and 4 may undergo migration is consistent with literature. Although the long-term effects of drained intraperitoneal gallstones due to bile duct perforation during cholecystectomy are not well understood, the first four post-operative months are specifically important and it is recommended that patients should be called in for check-up during this period in order to perform clinical evaluation of any possible complications (19–25). In a study in which the effect of scattered bile and gallstones in the peritoneal cavity was investigated, adhesion development was found in an average of 70 % of the subjects injected with sterile and infected bile (2). We also obtained similar results.

A combination of intraperitoneal bile and gallstone increases the frequency of adhesion formation. In experimental studies it is reported that approximately 70 % of intraperitoneally administered bile and gallstone give rise to adhesion formation (2). Nevertheless, it is suggested that due to the relatively large volume of bile and gallstone used in animal studies compared to the subjects' sizes, severe and frequent complications of this magnitude should not be anticipated in clinical practice. Based on the

clinical studies, it will take time to discover a definite evidence of the clinical importance and frequency of septic complications that may develop due to drained gallstones. Discarding the infected bile and gallstones in the peritoneal cavity may lead to serious events such as adhesion and septic complications; as a result, it is necessary to remove the stones as much as possible. It is not always viable to remove all gallstones placed in the peritoneal cavity during laparoscopic cholecystectomy. The most appropriate approach in the management of drained gallstones is not known.

According to literatute reports, it is necessary to perform clinical and laboratory follow-ups of patients during the first four months in conditions where the peritoneal cavity has drained gallstones associated with perforation of the bile duct during laparoscopic cholecystectomy (18). Nonetheless, nidus formations due to these gallstones and development of intra-abdominal abscesses even many years after surgery have been reported (8).

It is reasonable to suggest that drained gallstones during laparoscopic cholecystectomy may lead to such complications. Consequently, it is imperative that all measures are taken to guarantee complete removal of gallstones from the abdominal cavity. Additionally, there is not enough evidence to support the fact that laparotomy should solely be performed in the identification and removal of drained stones. The most common and appropriate approach accepted by most surgeons under this condition is the „wait and see“ policy. We are of the opinion that more extensive and definite results may be obtained regarding this subject by increasing the study population of subsequent experimental studies.

References

1. Easter DW. A Surgeon’s Perspective on Laparoscopic Cholecystechtomy. AJR 1991; 157: 241—242.

2. Johnston S, O’Malley K, McEntee G, Grace P, Smyth E, Bouchier-Hayes D. The need to retrieve the dropped stones during laparoscopic cholecystectomy. Am J Surg 1994; 167: 608—610.

3. Keskin A.Bostanoglu S, Atalay F, Akoglu M, Elbir O, Seven C. Laparoskopik kolesistektomi: 1270 olgunun analizi. End.-Lap. ve Minimal Invaziv Cerrahi 1996; 3: 168—171.

4. Way LW. Trends in the treatment of gallstone disease. Am J Surg 1989; 158: 251—253.

5. Perissat J. Laparoscopic cholecystectomy. The European Experience Am J Surg 1993; 165: 444—449.

6. Peters JH, Gibbons GD, Innes JT, Nichols KE, Front ME, Roby SR, Ellison EC. Complication of laparoscopic cholecystectomy. Surgery 1991; 110: 769—777.

7. Williams LF Jr, Chapman WC, Bonau RA, McGee EC Jr, Boyd RW, Jacobs JK. Comparison of laparoscopic cholecystectomy with open cholecystectomy in a single center. Am J Surg 1993; 165: 459—465.

8. Fitzgibbons RJ Jr, Annibali R, Litke BS. Gallbladder and gallstone removal, open versus closed laparoscopy, and pneumoperitoneum. Am J Surg 1993; 165: 497—504.

9. Gadacz TR, Talamini MA, Lillemoe KD, Yeo CJ. Laparoscopic Cholecystectomy. Surg Clin North Am 1990; 70: 1249—1262.

10. Nessar M. Laparoskopik kolesistektomi komplikasyonlarý ve korunma yöntemleri. End-Lap. ve Minimal Invaziv Cerrahi Derg 1994; 1: 55—60.

11. Zorluoglu A, Özgüc H, Yilmazlar T, Güney N. Is it necessary to retrieve dropped gallstones during laparoscopic cholecystectomy. Surg Endoscopy 1997; 11: 64—66.

12. Saunders KD, Cates JA, Roslyn JJ. Pathogenesis of Gallstones. Surg Clin North Am 1990; 70: 1197—1216.

13. Deziel DJ, Millikan KW, Economou SG, Doolas A, Ko ST, Airan MC. Complications of laparoscopic cholecystectomy: a national survey of 4,292 hospitals and an analysis of 77,604 cases. Am J Surg 1993; 165: 9—14.

14. Keskin A, Bostano•lu S, Atalay F, Elbir O, Seven C, Arda K. Laparoskopik kolesistektomide laparotomiye konversiyon. End.-Lap. ve Minimal Invaziv Cerrahi Derg 1996; 3: 107—110.

15. Ponsky JL. Complications of laparoscopic cholecystectomy. Am J Surg 1991; 161: 393—395.

16. Brown E, Hawasli A, Lloyd L. Laparoscopic cholecystectomy; Morbidity and mortality a community teaching institution. J Laparoendosc Surg 1993; 3: 13—18.

17. Fried GM, Barkun JS, Sigman HH, Joseph L, Clas D, Garzon J, Hinchey EJ, Meakins JL. Factors determining conversion to laparatomy in patients undergoing laparoscopic cholecystectomy. Am J Surg 1994; 167: 35—39.

18. Graber JN, Schultz LS, Ptetrafitta JJ, Hickok DF. Complications of laparoscopic cholecystectomy:a prospective review of an initial 100 consecutive cases. Lasers Surg Med 1992; 12: 92—97.

19. Ponce J, Cutshall KE, Hodge MJ, Browder W. The lost laparoscopic stone. Potential for long-term complications. Arch Surg 1995; 130: 666—668.

20. Schroeyers P, Mansvelt B, Bertrand C, de Neve de Roden A. Complications of laparoscopic cholecystectomy. Free intraperitoneal calculi. Ann Chir 1994; 48: 641—643.

21. Steerman PH. Delayed peritoneal-cutaneous sinus from unretrieved gallstones. Surg Laparosc Endosc 1994; 4: 452—453.

22. Thompson J, Pisano E, Warshauer D. Cholelithoptysis: an unusual complication of laparoscopic cholecystectomy. Clin lmaging 1995; 19: 118—121.

23. Wetscher G, Schwab G, Fend F, Glaser K, Ladurner D, Bodner E. Subcutaneous abscess due to gallstones lost during laparoscopic cholecystectomy. Endoscopy 1994; 26: 324—325.

24. Zarras K, Graupe F, Hansen O. Late abscess after laparoscopic cholecystectomy caused y lost gallstones. Chirurg 1996; 67: 1047—1049.

25. Vadlamudi G, Graebe R, Khoo M, Schinella R. Gallstones implanting in the ovary. A complication of laparoscopic cholecystectomy. Arch Pathol Lab Med 1997; 121: 155—158.

26. Andersson R, Tranberg KG, Bengmark S. Roles of bile and bacteria in biliary peritonitis. Brit J Surg 1990; 77: 36—39.

Received March 6, 2009.
Accepted January 5, 2010.