Bratisl Lek Listy 2010; 111 (3)
115 – 120

EXPERIMENTAL STUDY

Synergistic effects of hyperbaric oxygen and granulocyte-colony stimulating factor on postoperative adhesion formation in a rat cecal abrasion model

Can Kece[1], Fahrettin Yildiz[1], Abdurrahman Simsek[1], M Tahir Ozer[1], Salih Deveci[2], Taner Ozgurtas[3], Serdar Sadir[4], Ahmet Korkmaz[4], Ozgur Korkmaz[1], Nail Ersoz[4], Turgut Tufan[1]

Gulhane Military Medical Academy, General Surgery, Ankara, Turkey. **cankece@gmail.com**

Abstract: *Purpose:* We investigated the synergistic effect of hyperbaric oxygen (HBO) and granulocyte-colony stimulating factor (G-CSF) on adhesion formation in rats.
Methods: 40 adult male Sprague-Dawley rats (250-350g) were divided into 4 groups. In group-1, no further management was undertaken. Group-2 received HBO therapy, group-3 was treated with 50ug/kg subcutaneous G-CSF once daily for 7 days following laparatomy and cecal abrasion and group-4 was given both G-CSF and HBO therapies. On the 7th day, all rats were sacrificed and adhesions were scored. Tissue samples from adhesions and peritonea and cecum wall were examined both pathologically and biochemically for tissue hydroxyproline content.
Results: No mortality occurred in study groups. When the groups were evaluated according to the adhesion numbers and grades, there was a statistically significant difference between the control and groups 3 and 4 ($P<0.001$). There was no statistically significant difference between groups 1 and 2 ($p>0.05$). HBO + G-CSF group was significantly different from control, HBO and G-CSF groups, regarding hydroxyproline contents ($p=0.005$). Inflammation and fibrosis did not differ significantly among the groups ($p=0.248$), ($p=0.213$).
Conclusion: HBO treatment could not reduce the adhesion formation alone. Combined use of HBO and G-CSF, has a markedly preventive effect on postoperative adhesion formation *(Tab. 1, Fig. 2, Ref. 57)*. Full Text (Free, PDF) *www.bmj.sk.*
Key words: adhesion formation, postoperative adhesions, GCSF, hyperbaric oxygen.

Postoperative intra-peritoneal adhesion formation is a distressing outcome in all types of surgical operations. Adhesions develop following abdominal surgery, as a part of the wound healing process and are lead to small-bowel obstruction, chronical abdominal pain, female infertility, difficult reoperative surgeries and cummulative costs of care (1, 2).

All underlying pathophysiologic features of this phenomenon have not been still fully understood. The mechanism and stages of this unsolved surgical problem, have some similarities with the physiological healing process. It represents as a result of an aberration of the routine healing route. There are many important systemic and local factors affecting this complex matter such as; surgery, ischemia/hypoxemia, trauma to the peritoneum and infection (3, 4). It is widely accepted that, ischemic wounds can be infected easily and ischemia and/or infection deteriorate wound healing process (5, 6). Since hypoxemia and tissue hypo-oxygenation are key factors that limit and aberrate healing stages, preventing ischemia has been one of the main goals of the studies. So it is logical to state that the correction of this hypoxic condition and maintenance of sufficient tissue oxygenation, through administration of supplementary oxygen particularly in hyperbaric conditions, can be therapeutically efficient in overall healing process. Hyperbaric oxygen therapy (HBO) consists of inhalation of 100% oxygen in a high pressure-environment. The high amount of oxygen is an essential nutrient factor for cellular energy metabolism, and it has an additional importance for collagen formation, new vessel growth and inflammatory phase of the wound healing process (7–12).

Although it is clear that many multifactorial processes are involved in the adhesion formation, one of the important phase of wound healing response is the inflammation phase. For that reason, many studies in humans and in animal models have been focused on the activation or alteration of the inflammation (13, 14). Granulocyte-colony stimulating factor (G-CSF) and granulocyte monocyte- colony stimulating factor (GM-CSF) are two of these agents that have been found effective in wound healing, especially in colonic anastomoses (14). Many beneficial effects of G-CSF and locally applied GM-CSF on chemotaxis, neutro-

[1]Gulhane Military Medical Academy, General Surgery, Ankara, Turkey, [2]Gulhane Military Medical Academy, Clinical Pathology, Ankara, Turkey, [3]Gulhane Military Medical Academy, Biochemistry, Ankara, Turkey, and [4]Gulhane Military Medical Academy, Physiology, Ankara, Turkey

Address for correspondence: Can Kece, MD, Numune Teaching and Research Hospital, Gastroenterologic Surgery Clinic, 61100, Trabzon, Turkey.
Phone: +90.462.2302301/1048, Fax: +90.462.2302300

phil phagocytosis, differentiation of monocytes, increasing the mononuclear cell infiltration and bactericidal activities have been revealed in some studies (14–22). Because of such features, GM-CSF has antimicrobial effects and enhances wound healing response (23).

Thus, in this study we aimed to examine the synergistic effects of HBO and G-CSF which are two new subjects of search on postoperative intra-peritoneal adhesion formation in a rat cecal abrasion model. This study is also important because of the use of these two agents togetherfor the first time for this purpose.

Methods

Animals

The Animal Studies Committee at Ankara Gulhane Military Medical Academy Hospital approved animal care and all experiments. 40 adult male Sprague-Dawley rats (250–350 g) were used for the study. The animal housing environment maintained a 12-hour light/dark cycle, a temperature of 22 °C, and allowed access to standard laboratory food and water ad libitum.

Experimental Protocol

All surgical procedures were performed by a single surgeon under aseptic conditions. Animals were initially anesthetized with 60 mg/kg intramuscular ketamine hydrochloride (Ketalar^{R}, Parke-Davis, Morris Plains, NJ).

For adhesion induction, we used a modified rat model of abdominal adhesion formation originally described by Krause et al (24); A midline abdominal incision, 4 cm in length, was applied. The cecum was put on gauze and abraded with a sterile dry 4x4 cm surgical gauze, until punctuate hemorrhage occurred on the surface of the cecum. Opposing areas of the abdominal wall and the parietal peritoneum were also abraded with a #11 scalpel. The cecum then was returned to its original location in the abdomen and the abdominal wall and subcutaneous skin were closed uninterrupted using Vicrylr sutures (Johnson & Johnson, Tokyo, Japan).

The animals were divided into 4 groups. In group 1 (n=10), no further management was applied. Group 2 (n=10), received HBO therapy only following laparatomy and cecal abrasion. In group 3 (n=10), the rats were treated with 50ug/kg subcutaneous G-CSF (Neupogenr, Basel, Switzerland) once daily for 7 days following laparatomy and cecal abrasion. Group 4 (n=10), was given both G-CSF and HBO therapies.

HBO treatment was started at the 3rd hour of the operation. Before HBO treatment, pressure cabin was washed out with 1 ATA oxygen for 10 min. Rats in groups 2 and 4 were taken under pressure at 2.5 atmosphere absolutely in a one-look test chamber 0.2 m^3 capacity and 20 bars maximum working pressure. Each session consisted of three 20-minute oxygen periods, two 5-minute air breaks, and 10-minute compression and decompression periods. So HBO was given as oxygen of 100 % at 2.5 ATA for 60 min and total HBO treatment time was 80 min. It was performed 4 times a day for the initial 4 days, and then 3 times a day for the following 3 days, for a total of 7 days. Total HBO application number was 14.

Animals were sacrificed and a wide U-shaped incision was made under costal margins to investigate the extent and the type of adhesion formation, 7 days later by an observer blinded to the identity of the experimental groups. Each animal was evaluated by using of modified scale devised by Evans et al (25). According to this scale, 0 = no adhesions, 1 = smooth adhesions splitting spontaneously or with weak traction, 2 = firm adhesions splitting by traction, and 3 = dense adhesions requiring sharp dissection. Next, cecum and the opposite parietal peritoneum and the adhesion areas were excised for both histopathology and biochemical examination for tissue-peritoneal hydroxyproline level measurement.

Tissue Hydroxyproline level measurement

Tissue samples were hydrolysed in 6M hydrochloric acid, at 105 °C for 18 hours and evaporated until they are dry. Hydroxyproline levels were analysed by colorimetric methods with Ehrlich's reagent (10g p-dimethylaminobenzaldehyde, 11 mL perchloric acid). Hydroxyproline contents were measured against standard concentrations and are expressed as microgram per milligram of tissue (26).

Pathologic Examination

Two samples with a mean size of 1 x 1 x 0.4cm from cecum wall and parietal peritoneum of each rat were examined. The samples were fixed in a 10 % formaldehyde solution. After dehydration, sections of 5-um thickness from paraffine blocks were

Tab. 1. The distribution of the number and grades of the adhesions, hydroxyproline contents and results of the pathologic examinations according to the study groups.

	Group 1	Group 2	Group 3	Group 4	p[d]
Number of adhesions	3 (0-5)	1 (1-3)	0 (0-1)[a,b]	0 (0-0)[a,b]	<0.001
Grade	3 (0-3)	2 (1-3)	0 (0-1)[a,b]	0 (0-0)[a,b]	<0.001
Inflammation	1 (1-1)	1 (1-3)	1 (1-2)	1 (1-2)	0.248
HPcontent (ug/mg of tissue)	73.4±31.40	51.3±16.41	44.7±4.10[a]	123.8±57.00[a,b,c]	0.005
Fibrosis	1 (0-2)	1 (1-3)	1 (0-2)	1 (0-3)	0.213

[a] – the differencefrom Group 1 was statistically significant (p<0.01), [b] – the difference from Group 2 was statistically significant (p<0.001), [c] – the difference from Group 3 was statistically significant (p<0.001), [d] – Kruskal-Wallis test, ug.hydprol/mg – microgram hydroxyprolinen/milligram wet weight

taken by a microtome. Under a light microscope these sections were examined after hematoxylin-eosin staining. Inflammations were investigated by examination of the quantitative density of inflammatory cells an types, mesotel morphology, cellular responses such as fibrosis. All of them were investigated by the same pathologist unaware of the study groups.

Statistical analysis

A sample size of 6 per group was required to detect at least 2-unit difference between control and any case group in number of adezyon with a power of 80 % at the 5 % significance level. Sample size estimation was calculated by using NSCC and PASS * statistical package program (Hintze, 2001). NCSS and PASS. Number Cruncher Statistical Systems. Kaysville. Utah). All analyses were performed using an SPSS (v.11.5) statistical software package. (SPSS, Chicago, 11, 5). Whether the distributions of HP content were normally or not were determined by using Shapiro Wilks test. Data were shown as mean±standard deviation or median (minimum – maximum), where appropriate. The differences among groups were evaluated by Kruskal Wallis test. When the p-value from the Kruskal-Wallis test statistics is statistically significant, multiple comparison test was used to detect which group differs from which others. A p value less than 0.05 was considered statistically significant.

Results

No mortality occurred in study groups. The distribution of the number and grades of the adhesions, hydroxyproline contents and results of the pathologic examinations according to the study groups are summarized in Table 1 and Figure 1.

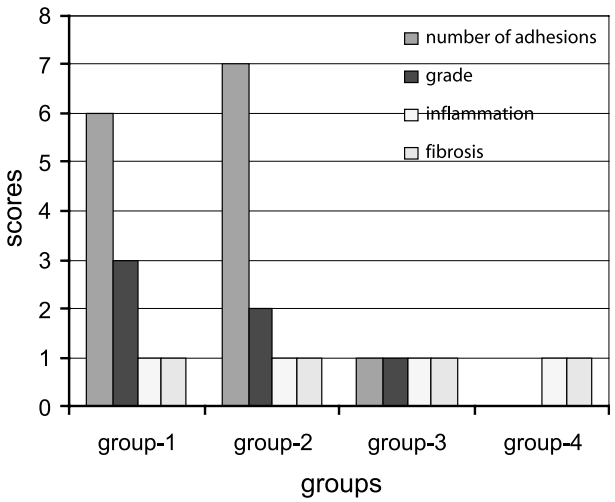

Fig. 1. Total adhesion numbers and grades, inflammation and the fibrosis of the groups. Statistically significant differences were observed between groups 1 and 4 and between groups 1 and 3 regarding the adhesion numbers and grades (p<0.001). In the pathologic analysis of the adhesion tissues, there was no statistically significant difference between any of the groups, including the control group, regarding inflammation and fibrosis (p>0.05).

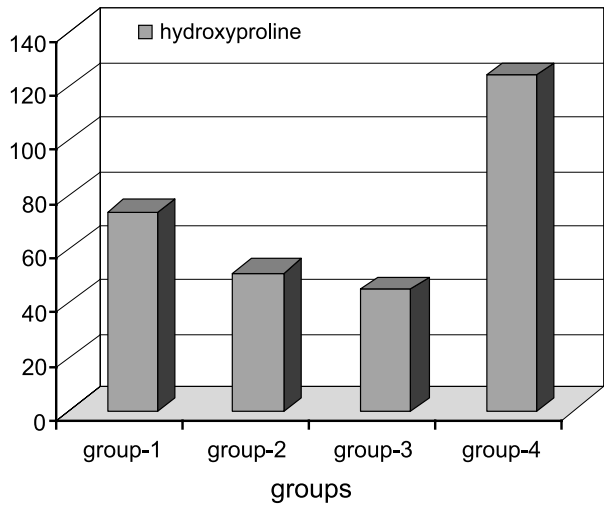

Fig. 2. Hydroxyproline contents of the groups. HBO+G-CSF group (group 4) was significantly different from control (group 1), HBO (group 2) and G-CSF (group 3) groups, regarding hydroxyproline contents (p=0.005).

There was a statistically significant difference between the control group (group 1) and groups 3 and 4, regarding adhesion grades (p<0.001). No statistically significant difference was observed between control and HBO group (p>0.05). Adhesion numbers were statistically significant in group 1, as compared to groups 3 and 4 (p<0.001). There was no statistically significant difference between groups 1 and 2 (p>0.05). For adhesion grades and numbers, there were significant differences between HBO (group 2) and G-CSF (group 3) groups pP<0.001).

Hydroxyproline levels of the intra-abdominal wounds are summarized in Table 1. There was a statistically significant difference between the control group and groups 3 and 4, regarding hydroxyproline content (p=0.005). There was no statistically significant difference between groups 1 and 2 (p>0.05), (Fig. 2). HBO + G-CSF group was significantly different from control, HBO and G-CSF groups, regarding hydroxyproline contents (p=0.005).

The results of the pathologic examinations of the study are summarized in Table 1. Regarding the pathologic analysis of the groups who received additional therapy, there was no statistically significant difference from the control group (p=0.248). Fibrosis also did not differ significantly among the groups (p=0.213).

Discussion

Results of the present study demonstrate that, combined using of hyperbaric oxygen (HBO) and granulocyte-colony stimulating factor (G-CSF), significantly decreases postoperative adhesion formation in a rat model. All types of abdominal surgeries can lead to peritoneal adhesions with significant morbidity and mortality (27, 28). Therefore, preventing or reducing the adhesion formation is one of the goals of the surgical studies

(29, 33, 37). In order to improve procedures against adhesion formation, numerous therapeutic agents and approaches have been used to reduce them, up to date (27–31). Unfortunately, the benefits from such methods remain unclear and currently there is no ideal, uniformly effective and accepted method worldwide. Adhesions cause small intestine obstructions, chronic abdominal pain and infertility and lead to serious morbidity and mortality by making the following surgery risky and difficult (27–31).

Formation of adhesions is a complicated process and the mechanism represents a variation in the normal physiological wound healing (32, 33). Adhesion formations seem to be a final level and cellular composition of this complex inflammatory storm (7, 9). Macrophages, fibroblasts and mesothelial cells have a major role during the stages of adhesion formation. Peritoneum seems to have an intrinsic fibrinolytic activity that breaks and regulate the wound healing. Clinical studies demonstrated that, there is a dynamic balance between pro-inflammatory and anti-inflammatory cytokines (34–36). Although many local and systemic factors have been shown to influence this dynamic balance, insufficient oxygenation probably is the most important one. Ischemia also is the most accused etiological factor in the adhesion formation and ischemic peritoneal injuries interfere with fibrinolytic activity (37). It is important to note that hypoxia aberrates wound healing pathway and also interrupts collagen synthesis. Since wound tissue oxygenation is the main indicator for the risk of infection, correcting hypoxemia and normalization of the cellular tissue oxygenation through the administration of supplemental oxygen, reduce the risk of infectious complications, restore wound healing and the oxidative function of neutrophils (38–40). Thanks to this, O_2 therapy can regulate collagen synthesis and deposition and the tensile strength of the wound, so it is stated that collagen can not be synthesised in the absence of molecular oxygen (41). It was reported that under hypoxic conditions, HBO treatment was found more effective and had a synergistic effect on healing when combined with antibiotics, so this therapy method has become increasingly popular in recent times (42, 43). Thus, one can expect that HBO increases wound healing and has a bacteriostatic and bacteriocidic effect.

G-CSF (Neupogenr, Basel, Switzerland); is an important cytokine that has specific effects on neutrophils. G-CSF predominantly increases growth and differentiation of the neutrophil function, i.e., chemotaxis, cytokin releases and phagocytosis (15, 44). In cancer patients, G-CSF and GM-CSF are widely used during the treatment of neutropenia caused by chemotherapy. Beneficial effects of these agents have been reported in the treatment of several clinical and experimental conditions, such as; dermal wounds, leg ulcers, pressure ulcers, cerebral ischemia, myocardial ischemia-reperfusion injuries, pulmonary hypertention, etc. (45–50). In experimental studies, it's found that, GM-CSF markedly accelerated wound healing especially in poorly healing ischemic wounds and had beneficial effects on impaired colon segments and anastomoses in rats undergoing long-term steroid and intraperitoneal 5-fluorouracil treatment (49–53). We used G-CSF subcutanously for significant improvement in the peritoneal healing.

In this present study, according to adhesion numbers, grades, inflammation, fibrosis and HP contents we did not find significant differences between the control and the group that was treated with HBO only. However, combined use of HBO and G-CSF was found to be effective with significantly different effect on adhesion formation. In the light of these results, we concluded that HBO treatment did not beneficially effect adhesions. However, there was a difference, almost reaching the level of significance, between the control group and the group that received both GCSF and HBO regarding adhesions ($p<0.001$). According to the pathologic examination, the formation of fibrosis was not significantly different in treatment groups compared with the control group ($p=0.213$). Adhesion numbers and grades did not differ significantly among the G-CSF only and HBO-G-CSF groups ($p>0.05$). However, HBO+G-CSF group was significantly different from G-CSF group, regarding hydroxyproline contents ($p=0.005$). Hydroxypyrolin (HP), which is the result of the degradation of collagen, develops by hydroxylation of prolin aminoacid and it is a major component of collagen. It keeps the stability of three part spiral structure of collagen through hydrogen bonds (53–57). So it is a good marker of wound healing. In this study, hydroxyproline levels in group 4 were found to be significantly different from that of the control ($p=0.005$), suggesting that HBO and G-CSF have an increasing effect on early collagen cross-linking, which improves healing. A study by Altuntas et al reveals that peritoneal HP levels are influential in adhesion of seprafilm to polipropilen mesh. In that study the authors claim that increases of HP level have a fundamental role on adhesion reducing effect of seprafilm (56). In Milligan, et al studies, since tissue hydroxypyrolin is a product of collagen breakdown, it is seen especially higher in a neutrophil group. In this study it is stated that especially in neutrophil dependent collagen break down process, tissue HP levels may be an indicator (57).

Hyperbaric oxygen and granulocyte colony-stimulating factor were preferred because of their potential synergistic effects on improving peritoneal defence mechanisms and a number of activities of inflammatory cell functions such as, neutrophil chemotaxis, migration, cell adhesion, synthesis, release of cytokines, tissue oxygenation, angioneogenesis and finally wound healing. Importantly, although hyperbaric oxygen therapy in the healing of chronic wounds found to be effective and thereby maintains cellular epithelial function, it does not appear that HBO treatment could reduce the adhesion formation alone. We have determined that HBO and G-CSF had markedly positive and protective effects on postoperative intra-peritoneal adhesion development, when used together. An understanding of the pathophysiologic and molecular basis of postoperative adhesion formation should expedite the improvement of new, easy applicable, cost-effective and universally accepted methods for reducing adhesion formation.

References

1. Tittel A, Treutner KH, Titkova S, Öttinger A, Schumpelic V. New adhesion formation after laparoscopic and conventional adhesiolysis. Surg Endosc 2001; 15: 44—46.

2. Ozogul Y, Baykal A, Onat D, Renda N, Sayek I. An experimental study of the effect of aprotinin on intestinal adhesion formation. Am J Surg 1998; 175: 137—141.

3. Fielding LP, Stewart—Brown S, Blesovsky L, Kearney G. Anastomotic integrity after operations for large bowel cancer: a multicenter study. Brit Med J 1980; 281: 411—414.

4. Khoury GA, Waxman BP. The healing process and sutured anastomoses. A review. Brit J Surg 1983; 70: 61—63.

5. Hamzaoglu I, Karahasanoglu T, Aydin S, Sahin DA. The Effects of Hyperbaric Oxygen on Normal and Ischemic Colon Anastomoses. Am J Surg 1998; 176: 458—461.

6. Stephens FO, Hunt TK. Effect of changes in inspired oxygen and carbon dioxyde tensions on wound tensile strength: an experimental study. Ann Surg 1971; 173: 515—519.

7. Hunt TK, Zederfeldt B, Goldstick TK. Oxygen and healing. Am J Surg 1969; 118: 521—525.

8. Knighton D, Silver I, Hunt T. Regulation of wound healing and angiogenesis-effect of oxygen gradients and inspired oxygen concentrations. Surgery 1981; 90: 262—270.

9. Tandara AA, Mustoe TA. Oxygen in Wound Healing—More than a Nutrient. World J Surg 2004; 28 (3): 294—300.

10. Ninikowski-2 Marx RE. Radiation injury to tissue. 447—503. In: Kindwall EP (Ed). Hyperbaric Medicine Practice Flagstaff AZ, Best Publishing Company, 1994.

11. Wattel F. European Committee Consensus Conference on Hyperbaric Oxygen in the Treatment of Foot Lesions in Diabetic Patients. ECHM. Glaxo-Welcome, France, 1998.

12. Buras J. Basic mechanisms of hyperbaric oxygen in the treatment of ischemia–reperfusion injury. Int Anesthesiol Clin 2000; 38 (1): 91—109.

13. Pados GA, Devroey P. Adhesions. Curr Opin Obstet Gynecol 1992; (4): 412—18.

14. Erdem E, Dinc S, Erdem D, Ustün H, Caydere M, Alagöl H. Effects of intraperitoneal chemotherapy and GM-CSF on anastomotic healing: an experimental study in rats. J Surg Res 2002; 108 (1): 1—6.

15. Roilides E, Walsh TJ, Pizzo PA, Rubin M. Granulocyte colony-stimulating factor enhances the phagocytic and bactericidal activity of normal and defective human neutrophils. J Infect Dis 1991; 163: 579—583.

16. Sartorelli KH, Silver GM, Gamelli RL. The effect of granulocyte colony-stimulating factor (G-CSF) upon burn-induced defective neutrophil chemotaxis. J Trauma 1991; 31: 523—529; discussion 529—530.

17. Raderer M, Kornek G, Hejna M, Koperna K, Scheithauer W, Base W. Topical granulocyte — macrophage colony-stimulating factor in patients with cancer and impaired wound healing. J Natl Cancer Inst 1997; 89: 263—270.

18. Arnold F, O'Brien J, Cherry G. Granulocyte monocyte-colony stimulating factor as an agent for wound healing. J Wound Care 1995; 4: 400—402.

19. Jyung RW, Wu L, Pierce GF, Mustoe TA. Granulocyte—macrophage colony-stimulating factor and granulocyte colony-stimulating factor: differential action on incisional wound healing. Surgery 1994; 115: 325—234.

20. Groves RW, Schmidt-Lucke JA. Recombinant human GM—CSF in the treatment of poorly healing wounds. Adv Skin Wound Care 2000; 13: 107—112.

21. Dinc S, Alagol H, Gulcelik MA, Ozbirecikli B, Kuru B, Renda N. Locally applied granulocyte—macrophage colonystimulating factor improves the impaired bowel anastomoses in rats with long-term corticosteroid treatment. World J Surg 2002; 26: 1208—1213.

22. Gulcelik MA, Dinc S, Bir F, Elitok O, Alagol H, Oz M. Locally applied molgramostim improves wound healing at colonic anastomoses in rats after ligation of the common bile duct. Can J Surg 2005; 48 (3): 213—218.

23. Jones TC. The effects of rhGM-CSF on macrophage function. Eur J Cancer 1993; 29 (Suppl 13): 10—13.

24. Krause TJ, Goldsmith NK, Ebner S, Zazanis GA, McKinnon RD. An inhibitor of cell proliferation associated with adhesion formation is suppressed by N,O-car-boxymethyl chitosan. J Invest Surg 1998; 11: 105—113.

25. Evans DM, McAree K, Guyton DP. Dose dependency and wound healing aspects of the use of tissue plasminogen activator in the prevention of intra-abdominal adhesions. Am J Surg 1993; 165: 229—232.

26. Jamall IS, Finelli VN, Que Hee SS. A Simple Method Determine Nanogram Levels of 4-Hydroxyproline in Biological Tissues. Analytical Biochemistry 1981; 112; 70—75.

27. Ellis H, Moran DJ, Thompson JN, Parker MC, Wilson MS, Menzies D et al. Adhesion-related hospital readmissions after abdominal and pelvic surgery: a retrospective cohort study. Lancet 1999; 353: 1476—1480.

28. Ellis H. The clinical significance of adhesions: focus on intestinal obstruction. Eur J Surg Suppl 1997; 577: 5—9.

29. Avital S, Bollinger T, Wilkinson JD, Marchetti F, Hellinger MD, Sands LR. Preventing intra-abdominal adhesions with polylactic acid film: an animal study. Dis Colon Rectum 2005; 48: 153—157.

30. Hull MG, Glazener CM, Kelly NJ. Population study of causes, treatment and outcome of infertility. Br J Surg 1985; 291: 693—710.

31. Arikan S, Adas G, Barut G, Toklu AS, Kocakusak A, Uzun H et al. An evaluation of low molecular weight heparin and hyperbaric oxygen treatment in the prevention of intra-abdominal adhesions and wound healing. Am J Surg 2005; 189 (2): 155—160.

32. Menzies D, Ellis H. Intestinal obstruction from adhesions — how big is the problem? Ann R Coll Surg Engl 1990; 72: 60—63.

33. Gomel V, Urman B, Gürgan T. Pathophysiology of adhesion formation and strategies for prevention. J Reprod Med 1996; 41: 35—41.

34. Menger MD, Vollmar B. Surgical trauma: hyperinflammation vs mmunosuppression? Langenbecks Arch Surg 2004; 389: 475—484.

35. Faist E, Schinkel C, Zimmer S. Update on the mechanisms of immunosuppression of injury and immunemodulation. World J Surg 1996; 20: 454—459.

36. Romeo C, Cruccetti A, Turiaco A, Impellizzeri P, Turiaco N, Di Bela C et al. Monocyte and neutrophil activity after minor surgical stres. J Pediatr Surg 2002; 37: 741—744.

37. Ellis H. The causes and prevention of postoperative intraperitoneal adhesions. Surg Gynecol Obstet 1971; 133: 497—511.

38. Grim PS, Gottlieb LJ, Boddie A, Batson E. Hyperbaric oxygen therapy. J Amer Med Ass 1990; 263: 2216—2220.

39. Tompach PC, Lew D, Stoll JL. Cell response to hyperbaric oxygen treatment. Int J Maxillofac Surg 1997; 26: 82—86.

40. Marx RE, Ehler WJ, Tayapongsak P, Pierce LW. Relationship of oxygen dose to angiogenesis induction in irradiated tissue. Am J Surg 1990; 160: 519—524.

41. Roberts GP, Harding KG. Stimulation of glycosaminoglycan synthesis in cultured fibroblasts by hyperbaric oxygen. Br J Dermatol 1994; 131: 630—633.

42. Knighton DR, Halliday B, Hunt TK. Oxygen as an antibiotic. A comparison of the effects of inspired oxygen concentration and antibiotic administration on in vivo bacterial clearance. Arch Surg 1986; 121: 191—195.

43. Wang J, Li F, Calhoun JH, Mader JT. The role and effectiveness of adjunctive hyperbaric oxygen therapy in the management of musculoskeletal disorders. J Postgrad Med 2002; 48: 226—231.

44. Tsuchiya M, Nomura H, Asano S, Kaziro Y, Nagata S. Characterization of recombinant human granulocyte colony—stimulating factor produced in mouse cells. EMBO 1987; 6: 611—616.

45. Kilic D, Sayan H, Gönül B. The effect of GM-CSF on glutathione and lipid peroxidation in a rat model. Eur J Surg Oncol 2000; 26: 701—704.

46. Shamseddine AI, Khalil AM, Kibbi AG, Abu Nasr TA, Seoud MA, El Saghir NS. Granulocyte macrophage-colony stimulating factor for treatment of chemotherapy Extravasation. Eur J Gynaecol Oncol 1998; 19: 479—481.

47. El Saghir NS, Bizri AR, Shabb NS. Pressure ulcer accelerated healing with local injections of granulocyte macrophagecolony stimulating factor. J Infect 1997; 35: 179—182.

48. Cetinkaya K. GM-CSF improves impaired anastomotic wound healing in rats treated with intraperitoneal mitomycin-C. Surgery Today 2005; 35 (4): 290—294.

49. Demirer S. Effect of recombinant human GM-CSF on the healing of colonic anastomosis in rats. J Invest Surg 2001; 14 (4): 221—225.

50. Ergin E. The effects of the immunomodulators on the colonic anastomosis in an experimental model of intraperitoneal sepsis. Hepatogastroenterology. 2004; 51 (56): 439—442.

51. Groves RW, Schmidt-Lucke JA. Recombinant human GM-CSF in the treatment of poorly healing wounds. Adv Skin Wound Care 2000; 13: 107—112.

52. Dinc S, Alagol H, Gulcelik MA, Ozbirecikli B, Kuru B, Renda N. Locally applied granulocyte-macrophage colony stimulating factor improves the impaired bowel anastomoses in rats with long-term corticosteroid treatment. World J Surg 2002; 26: 1208—1213.

53. Erdem E, Dinc S, Erdem D, Ustun H, Caydere M, Alagol H. Effects of intraperitoneal chemotherapy and GM-CSF on anastomotic healing: an experimental study in rats. J Surg Res 2002; 108: 1—6.

54. Haney AF, Doty E. The formation of coalescing peritoneal adhesions requires injury to both contacting peritoneal surfaces. Fertil Steril 1994; 61: 767—775.

55. Van Hinsbergh VW, Kooistra T, Scheffer MA, Hajo van Bockel J, van Muijen GN. Characterization and fibrinolytic properties of human omental tissue mesothelial cells: comparison with endothelial cells. Blood 1990; 75: 1490—1497.

56. Altuntas I, Tahran O, Delibas N, Cetin R, Süt•ü R. Seprafilm reduces adhesions to polypropylene mesh and increases peritoneal HP. Am Surg 2002; 68: 759—761.

57. Milligan DW, Raftery AD. Observations on the pathogenesis of peritoneal adhesions: a light and electron microscopical study. Brit J Surg 1974; 61: 274—278.

Received November 2, 2009.
Accepted January 5, 2010.