Bratisl Lek Listy 2010; 111 (2)
93 – 96

CLINICAL STUDY

Phacoemulsification of mature and hard nuclear cataracts

Ilavska M, Kardos L

Ophthalmology Ward St. Lucas Hospital Galanta, Slovakia. **bll@fmed.uniba.sk**

Abstract: The aim of the study was to compare the best corrected visual acuity (BCVA) before and at the lst day after the cataract surgery for mature or the hard nuclear cataract. The phacoprobe NeoSoniX equipment Legacy (Alcon Laboratories) was used for the cataract surgery. Trypan blue for vital staining of the anterior capsule was used in case of the white cataract. The prevalence and the effect of the complication on BCVA were evaluated. 561 eyes were operated for the cataract. 57 (10.16 %) had cataract grade NO4-NC6 and NC4-NC6 (LOCS III). Postoperative complications were: the transient edema of cornea in 8 eyes (14 %), one case of (1.75 %) erosio cornea caused by patient and in one case (1.75 %) the intraocular pressure was elevated for a short time.

Conclusion: The results of this study confirm that phacoemulsification is an appropriate method for the resolution of cataracts at advanced stages *(Tab. 2, Fig. 3, Ref. 24).* Full Text (Free, PDF) *www.bmj.sk.*

The advanced stages of opacification of lens – the mature cataract (the total opacification of nucleus and cortex of lens) (7) and nuclear sclerosis at the senile cataract are possible sources of intraoperative and postoperative complications. The improving of the technique and quality of surgery's equipment diminishes the number and the magnitude of complications.

Growing of lens, as a result of their aging, is playing an important role in the patophysiology of glaucoma (phacomorphic, phacolytic) (3, 7). The hard nuclear opacification is characteristic for the pseudoexfoliation syndrome, most frequent in the age of 75–84 years. This fact with a small pupil and insufficient lens zonular aparatus can lead to the serious course of surgery with complications (zonular dialysis, ruptura of posterior capsula with vitreous lost, fibrinous reaction after surgery) (17, 18). The disturbance of transparency of lens avoids the examination of retina and serious diseases of retina are not established (age related macular degeneration (ARMD) diabetic retinopathy (DR)).

Results of the surgery is dependent on the condition of eye before the operation (corneal endothelium, retina), on the technique of surgery and intraoperative and postoperative complications. The staining of anterior capsula by vital staining with trypan blue is used for creating an anterior capsulorhexis (5). The ocular viscoelastic divices (OVD) are used to protect endothelium of cornea from surgical trauma. OVD maintain the depth of the anterior chamber and ensure the safe manipulation in the anterior chamber (11). Modulation of the ultrasound energy, pulled to the eye (burst, pulse mode), torsional movement of the phacotip Neosonix equipment Legacy (the Everest technology from Alcon Laboratories) is lowering the amount of energy used for the emulsification of the lens (15).

Ophthalmology Ward St. Lucas Hospital Galanta, Slovakia

Address for correspondence: M. Ilavska, MD, Ophthalmology Ward St. Lucas Hospital Galanta, Hodska 378/38, SK-924 22 Galanta, Slovakia.

The toxic syndrome can affect a visual acuity after the cataract surgery (9, 23).

The aim of the study was to evaluate the central visual acuity after the cataract surgery for advanced stages of cataract when the phacoprobe NeoSonix was used for the phacoemulsification. The study deals with the intraoperative and postoperative complications. The influence of complications on visual acuity was considered.

Material and methods

The group of patients included patients undergoing the cataract surgery at the Ophthalmology ward of the St. Lucas Hospital a.s. Galanta.

561 eyes were operated in the period 05/2007–04/2008. 57 (10.16 %) eyes had the mature or the hard nuclear cataract and were operated using the phacoprobe NeoSonix. The proportion man to women was 37/20. The average age in the group was 70.8 years, the range of age was 45 to 89 years.

The best corrected visual acuity (BCVA) according to the Snellen optotypes, intraocular pressure measured by aplanation tonometry, biomicroscopic investigation and evaluation of retina was done before and at the firth day after surgery. The ultrasound examination was done to detect the retinal detachment. The Lens Opacities Classification System – LOCS III was used for the classification of opacification of the lens (6). Grade NO4 – NO6 and NC4 – NC6 (NO – nuclear opalescence, NC – nuclear colour) of opacification of lens was the criterion for including the patient to the study. The calculation of power of intraocular lens was done by keratometry and ultrasonic measurement of the axial length of the eye by the OcuScan RXP (Alcon Laboratories) using the SRK II formula. The surgery was performed by two surgeons in local anaesthesis by drops of oxybuprocain

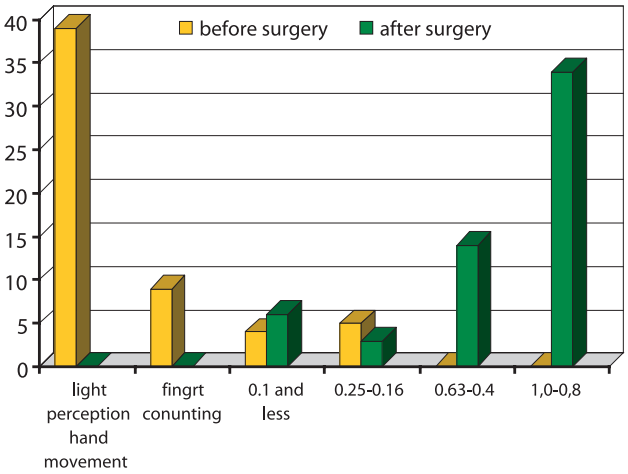

Fig. 1. BCVA before and 1st day after surgery.

hydrochloridum 0.4 % or the peribulbar anaesthesis – trimecain hydrochloridum 1 % with bupivacain hydrochloridum 0.5 %. The phacoemulsification was used in all procedures. Viscoelastic hydroxypropylmetylcelullose 2 % or 2.5 % was used. In case of the cataract grade N06 NC6, trypan blue was used for staining the anterior capsula. Hydrodissection and hydrodelineation was performed after the creation of capsulorhexis (CCC). The phacoprobe NeoSoniX with Kelman tip 0.9 mm 30 degrees angulated was used. The technique of dividing nucleus was divide, stop and chop. The intraocular lens (IOL) was implanted by the injector (hydofilic or hydrofobic IOL) or by the forceps (hard polymethylmethacrylate – PMMA, anterior chamber PMMA IOL). Cefuroxim 1 mg was injected to the anterior chamber at the end of surgery.

The BCVA before and after thesurgery was compared in this group of patients. The prevalence and the effect of complications on visual acuity was evaluated.

Results

The procedures of cataract surgery were evaluated in the retrospective study.

In the group of 57 eyes, the BCVA the hand movement or the light perception before the operation had 39 eyes (68.42 %)

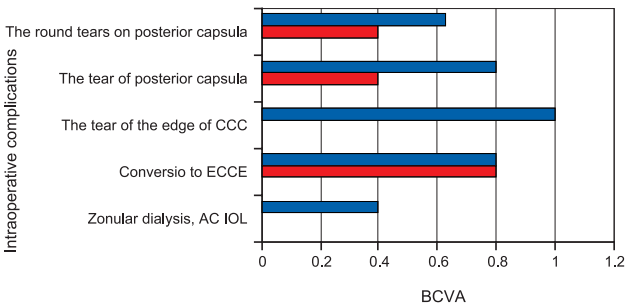

Fig. 2. The intraoperative complications and BCVA.

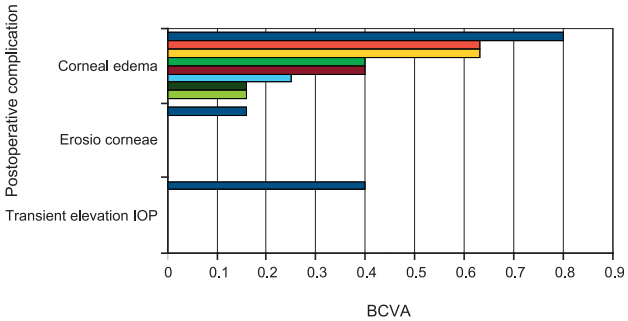

Fig. 3. Postoperative complications and BCVA.

with the cataract grade NO6 NC6. The BCVA the finger counting had 9 eyes (15.79 %), 5 with the cataract grade NO6 NC6, 3 eyes with the cataract grade NO5 NC5. The BCVA 0.1 or less had 4 eyes (7.01 %) with the cataract grade NO5 NC5 and 0.25–0.16 had 5 eyes (8.78 %) with the cataract grade NO4 NC5. In one eye with the light perception, the pseudoexfoliative syndrome was present.

At the first day after the surgery, BCVA 1.0–0.8 had 34 eyes (59.65 %). The BCVA 0.63–0.4 had 14 eyes (23.56 %), 0.25–0.16 had 3 eyes (5.26 %), 0.1 had one eye (1.75 %), less than 0.1 had 5 eyes (8.78 %). The results are shown on the Figure 1.

The trypan blue was used for the vital staining of the anterior capsule in 20 eyes (35.08 %). The hydrophilic foldable intraocular lenses were implanted in 47 cases, the hard PMMA intraocular lenses were implanted in 6 cases, the hydrofobic intraocular lenses were implanted to 3 eyes and the anterior chamber IOL was used in one case.

In the group of 57 eyes, there were following intraoperative complication: 2x (3.5 %) small round tear of the posterior capsule with an intact vitreous face, 2x (3.5 %) tear on the posterior capsula, 1x tear in the edge of capsulorhexis in case of the intumescent cataract, lx (1.75 %) zonular dialysis and 2x (3.5 %) the surgery was converted to the extracapsular extraction. The postoperative complication were the transient edema of cornea in 8 eyes (14 %), 1x (1.75 %) erosio of cornea caused by patient and 1x (1.75 %) the intraocular pressure was elevated for a short time. The summary of CVA in the cases of complication is shown on the Figs 2 and 3 and Tabs 1 and 2.

The endophthalmitis and the anterior segment toxic syndrome were not observed in this study.

Discussion

The cataract surgery using a phacoemulsification is the most using kind of resolution the cataract. The phacoemulsification using a vital staining of the anterior capsule is an appropriate method for the resolution of mature cataracts (5, 10, 19). In the group of 561 eyes in the evaluated period 57 (10.16 %) were mature or hard nuclear. 14 patients were older than 70 years, 4 patients were older than 80 years. The oldest woman was 89 years old. The phacoprobe NeoSoniX, used at surgery in 57 eyes,

Tab. 1. The intraoperative complications.

Intraoperative complications	Number of eyes
The round tears on posterior capsula	2 (3.5 %)
The tear of posterior capsula	2 (3.5 %)
The tear of the edge of CCC	1 (l.75 %)
Conversio to ECCE	2 (3.5 %)
Zonular dialysis and implantation of AC IOL	1 (1.75 %)
Total	57 (100 %)

Tab. 2. Postoperative complications.

Postoperative complication	Number of eyes
Corneal edema	8 (14 %)
Erosio corneae	1 (1.75 %)
Transien elevation IOP	1 (1.75 %)
Total	57 (100 %)

utilised longitudinal and torsion movement of the ultrasound probe with a mechanical effect side to side, to emulsifide the lens. The advantage of this is the shortening of surgery time, lowering the ultrasound energy pulled to the eye and decreasing the influence to intraocular structure, mainly the endothelium of cornea (15, 12, 22). The technique of dividing the nucleus to two pieces and their next fragmentation to smaller parts using the second instrument – Sinskey hook or vertical choper was used by surgeons (4, 12).

52 eyes (91 %) had BCVA 0.1 and less before the operation. After this procedure, 34 eyes (59.65 %) had BCVA 1.0–0.8. 14 eyes had BCVA 0.63–0.4. Together, 84.21 % eyes had BCVA much better than before surgery. 3 eyes (5.26 %) had the transient corneal edema. 6 eyes (10–52 %) had BCVA 0–1 and less. The advanced stage of age related macular degeneration (ARMD) with disorders of the retinal pigment epithelium was subsequently found in these cases. In one case, the erosio of the cornea was caused by patient.

The prevalence of complication is different in studies depending on the type of the evaluated group of patients and the type of cataract (16, 20, 24). When the different parts of the surgery are compared, rupture of the posterior capsula in phacoemulsification is consider the most common complication, 59 % (2, 21). In our group of 571 eyes, the rupture of the posterior capsula appeared only 5x (0.875 %) in the group of 57 cases of mature and hard cataracts.

In the group of 57 eyes, the round small rupture on posterior capsula occurred 2x (3.5 %). IOL was implanted to the bag. Two ruptures of posterior capsula occurred in the end of the phacoemulsification. In all 4 cases, the surgery ended by phacoemulsification without the loss of lens fragments to vitreous. The anterior vitrectomy was not necessary. Vitreous was not present in the anterior chamber.

Phacoemulsification was changed to the extracapsular cataract extraction in two eyes of a 86 year old woman for a very hard cataract. The BCVA of this eyes after the surgery was 0.8 in both eyes, the retinal changes were present (ARMD). The zonular dialysis more than 2/3 of radius was recorded in a 88 year old woman. She was operated on for the open angle glaucoma (trabeculectomia with basal iridectomia) and the posterior synechie were present. The anterior chamber IOL was implanted in this case for a lower risk of complication compared to the scleral fixation of IOL (8). The BCVA in this patient at the first day after the surgery was 0.4, after one week 0.8 and stayed stabilized for one year after the surgery.

The following postoperative complication were recorded: the transient edema of cornea was present in 8 eyes (14 %) and healed spontaneously in three days. The BCVA 0.8–0.5 had 5 eyes and the BCVA 0.25–0.16 had 3 eyes. The average age of these patients was 72 years. The edema was present 4x in case of the rupture of posterior capsula.

The elevation of the intraocular pressure (IOP) is more often in complicated cases of the surgery (1). In one case it was present in the evaluated group of eyes. It was the patient with the chronic open angle glaucoma, where the synechiolysis was done prior to phacoemulsification. This problem was solved by a short application of antiglaucomatic monotherapy. The erosio of epithelium of cornea was present in one case and it was caused by patient. Erosio was healed in two days. The patients was suffered from senile dementia.

The prevalence of clinically and by fluorescein angiography (FA) established cystoid macular edema (CME) after an uncomplicated cataract surgery by the phacoemulsification is minimal, 0–9.1 % (13). In this group of patients, the CME clinically significant and biomicroscopicaly present did not occur. FA was not done.

The prevalence of endophtalmitis after the surgery varies depending on the incision localisation from 0.02 % (other than corneal incision) to 0.05 % (corneal incision) (14). In this group of 571 eyes, endophthalmitis was not present.

The age related macular degeneration with disorders and atrophy of the retinal pigment epithelium was found in 6 eyes after the surgery, drusen of Bruch's membrane 1x, the pseudoexfoliation syndrome 1x, myopic changes of retina lx and opacites of vitreous 2x.

Conclusion

The results of the study confirm that phacoemulsification is an appropriate method for the resolution of cataracts at advanced stages. The unexpected complications can occur during this procedure, but the modern techniques of the cataract surgery can prevent them. If the complications occur, new technique helps in their solution.

References

1. Brazitikos PD, Balidis MO, Tranos P. Sulcus implantation of a 3-piece, 6.0 mm optic, hydrophobic foldable acrylic intraocular lens in phacoemulsification complicated by posterior capsule rupture. J Cataract Refract Surg 2002; 28 (9): 1618—1622.

2. Guttman CH. Prognosis generally good after vitreous loss during cataract surgery. Eurotimes 2005; 10 (3): 27.

3. Hejsek L, Pašta J. Ultrazvuková biomikroskopie oka před a po operaci katarakty. Čes Slov Oftal 2006; 62 (1): 27—33.

4. Chee S. Management of the hard posterior polar cataract. J Cataract Refract Surg 2007; 33 (9): 1509—1514.

5. Chung CF, Liang CC, Lai JSM. Safety of trypan blue 1 % and indocyanine green 0.5 % in assisting vizualization of anterior capsule during phacoemulsification in mature cataract. J Cataract Refract Surg 2005; 31 (5): 938—942.

6. Chylack LT, Wolfe JK, Singer DM. The Lens Opacities Classification System III. Arch Ophtalmol 1993; 111 (6): 831—836.

7. Kanski JJ. Clinical ophtalmology. Second edition. Butterworth-Heinemann Ltd., 1989, pp. 241—242.

8. Kwong YY, Yuen HK, Lam RF. Comparison of outcomes of primary scleral — fixated versus primary anterior chamber intraocular lens implantation in complicated cataract surgeries. Ophtalmology 2007; 114 (1): 80—85.

9. Larkin H. Amorphous anatomy of a toxic anterior segment syndrome outbreak. Eurotimes 2007; 12 (6): 14.

10. Laureano JS, Coroneo MT. Crystalline lens capsulae staining with trypan blue. J Cataract Refract Surg 2004; 30 (10): 2046—2049.

11. McGrath D. OVDs hold the key to safer, easier cataract surgery. Eurtimes 2007; 12 (9): 6.

12. McGrath D. Strategies for getting to grips with brunescent cataracts. Eurotimes 2007; 12 (9): 7.

13. Mentes J, Erakgun T, Afrashi F. Incidence of Cystoid Macular Edema after Uncomplicated Phacoemulsification. Ophtalmologica 2003; 217: 408—412.

14. Miller JJ, Scott IU, Flyn HW. Acute-onset endophtalmitis after cataract surgery (2000—2004): incidence, clinical settings, and visual acuity outcomes after treatment. Amer J Ophtamol 2005; 139 (6): 983—987.

15. Nuijts R. Modern techniques can significantly reduce endothelial cell loss after cataract surgery. Eurotimes 2008; 13 (1): 10—11.

16. Osher RH, Yu BC, Koch DD. Posterior polar cataracts: a predisposition to intraoperative posterior capsular rupture. J Cataract Refract Surg 1990; 16: 157—162.

17. Potocký M, Černák A, Vodrážková E. Operácia katarakty pri pseudoexfoliatívnom syndróme. Čes Slov Oftal 2000; 56 (4): 246—250.

18. Potocký M. Pseudoexfoliatívny syndróm a jeho význam pre operáciu sivého zákalu. Čes Slov Oftal 2003; 59 (6): 422—432.

19. Rangaraj NR, Ariga M, Thomas J. Comparison of anterior capsulae electron microscopy findings with and without trypan blue stain. J Cataract Refract Surg 2004; 30 (10): 2241—2242.

20. Siatiri H, Moghimi S. Posterior polar cataract: minimizing risk of posterior capsule rupture. Eye 2006; 20: 814—816.

21. Taskapili M, Engin G, Kaya G. Single — piece foldable acrylic intraocular lens implantation in the sulcus in eyes with posterior capsulae tear during phacoemulsification. J Cataract Refract Surg 2005; 31 (8): 1593—1597.

22. Tija KF. Efficiency of Torsional Versus Longitudinal Ultrasound. Cataract Refract Surg Today 2008; 3 (4): 33—34.

23. Toxic anterior segment syndrome after cataract surgery — Maine, 2006. MMWR — Morbidity and Mortality Weekly Report 2007; 56 (25): 629—630.

24. Vasavada A, Singh R. Phacoemulsification in eyes with posterior polar cataract. J Cataract Refract Surg 1999; 25: 238—245.

Received April 15, 2009.
Accepted November 17, 2009.