Bratisl Lek Listy 2009; 110 (12)
796 – 801

MORPHOLOGICAL STUDY

"Bochdalek" skull (syngnathia): CT examination

Klepacek I[1,2], Nanka O[1]

Department of Anatomy, First Faculty of Medicine, Charles University, Prague, Czech Republic.
klepacek@seznam.cz

Abstract: Bony fusion of the jaws (syngnathia) without any other anatomic oral anomalies is an unusual condition. It is believed that important factors can be congenital. Some cases with combination of cleft palate, aglossia, and soft or bony adhesion between the maxilla and mandible have been reported. Congenital syngnathia could also occur with Treacher-Collins syndrome, pterygium syndrome and van der Woude syndrome. In this study, girl skull with jaw anomaly depicted by prof. Bochdalek in XIX. century was re-examined using CT method to explain possible mechanism of this anomaly development. Our report presents a case of syngnathia with bilateral vision where mandible, maxilla, zygomatic and palatal bones are mutually connected. CT findings strongly support the idea about of mechanical trauma triggering a chain of bone disturbances in facial skeleton. With high probability most of the teeth were extracted later to keep the oral cavity open *(Fig. 9, Ref. 32)*. Full Text (Free, PDF) *www.bmj.sk.*
Key words: bony syngnathia, facial disturbances, maxilla, mandible, Bochdalek.

Well-preserved woman skull with immobile jaws (bone syngnathia) is exhibited in the Anatomical museum of the First Faculty of Medicine in Prague. Macroscopical depiction of this skull focused on its surface, was made by Vincenc Alexander Bochdalek, world-known anatomist in XIX. century (32), and was published in 1871 (1). The skull has been saved from this time in museum collections as one of unusual, infrequent and rare skeletal findings with unclear etiology. There is no information about internal structure of this anomaly. Only a very few medical information is known about the afflicted girl life, no objectives related to family case-history and even no other bones of the girl's skeleton are available. Following an endeavor to clarify the mechanism resulting in this skull anomaly we use 3D examination based on CT method (ICCATvision) which helped us to describe the intracranial structure. Fundamental questions are: first, which factors causing this defect are most probable – prenatal or postnatal; second, how does this defect develop? Maxillomandibular fusion is a serious anomaly strongly handicapping a person. It varies from simple mucosal adhesions (synechiae) to extensive bony fusion (syngnathia).

Congenital osseous syngnathia, without any associated systemic or intraoral anomaly (2, 3) is a sporadic condition. Syngnathia seems to be even a more rare entity (4, 5, 7, 9) and only incomplete and vague information can be gathered because their description is vague, terminology is confusing and only limited useful conventional imaging is applied (2, 7, 8, 10, 11, 12). One of more detailed reviews presented by Dawson and coworkers (8) provide no evidence of any familial tendency, history of drug and toxin exposure or consanguinity.

Syngnathiae are usually discussed in association with other anatomical oral and maxillofacial anomalies. Some of such cases have been reported in the literature in combination with various syndromes (e.g. cleft lip, cleft of hard and soft palate (31), soft tissue synecchiae, hypoplasia of the proximal mandible, hemifacial microsomia, cleft of mandible, bifid tongue, small or absent tongue, aglossia, popliteal pterygium syndrome (11), van der Woude syndrome, aglossia-adactylia syndrome (17), oral, temporomandibular (zygomaticomandibular) fusion and some other regional and systemic anomalies (4, 19)).

Methods

We used an iCATvision commercial software programme (imaging Sciences International Version: 1.6.2.0) to image intraosseal details of subjected skull. This programme permits using 3DVR Version 5.0 to create panoramic maps based on obtained data as well as video sequences of the choosen skull parts where distances among structures can be measured and evaluated mathematically.. This is a special technique to show in detail images of structures lying in a predetermined plane of tissue, while blurring or eliminating detail due to images of structures in other planes.

Findings

Skull of a young girl (Margaretha Tonner; *April 18, 1762– July 25, 1780 (see general description published in Bochdalek

[1]Department of Anatomy, First Faculty of Medicine, Charles University, Prague, and [2]Institute of Anatomy, Third Faculty of Medicine, Charles University, Prague, Czech Republic

Address for correspondence: I. Klepacek, MD, PhD, Dept of Anatomy, First Faculty of Medicine, Charles University, U nemocnice 2, CZ-120 00 Prague, Czech Republic.
Phone:

Acknowledgement: relate to Dr. René Foltán for kind assistance during work on iCATvision CT apparatus and to Věra Šenková for photo assistance.

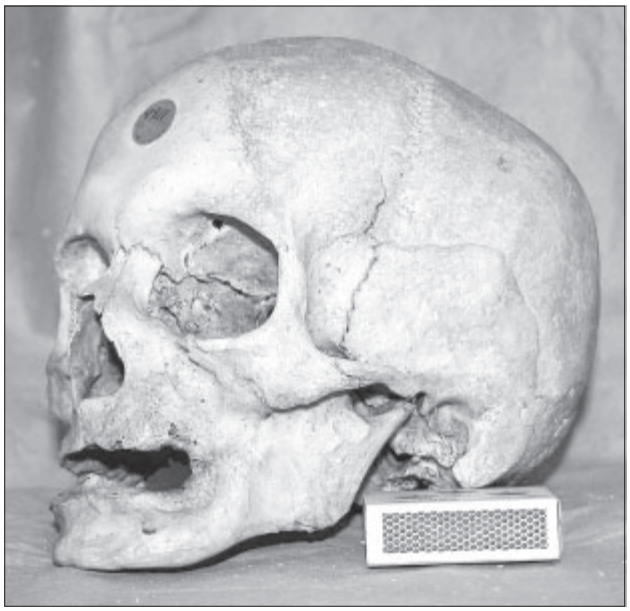

Fig. 1. "Bochdalek" skull with syngnathia; on view in skull exposition in museum of Department of Anatomy, 1st Faculty of Medicine, Charles University, Prague.

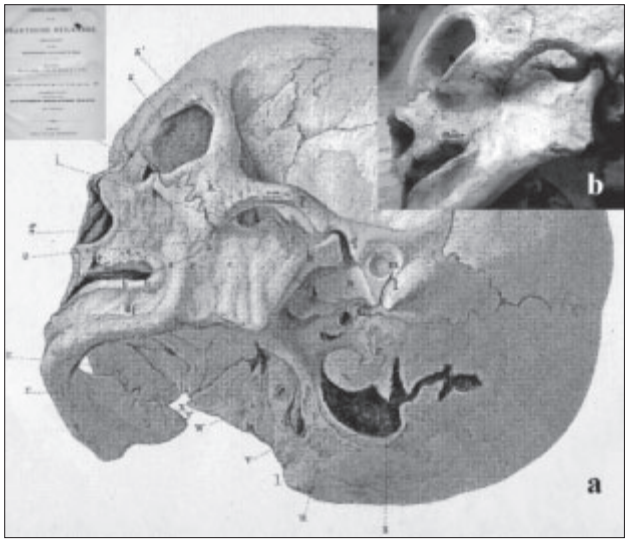

Fig. 2a, b, c. Semi axial view of the skull where line of mandible-zygomatic-maxilla bones fusion is seen; a – original drawing from Bochdalek study; b – detailed photo of this line (Olympus E 30); right lower corner – initial page of a textbook where it was published. Note of complete adhesion of the jaws, which extended posteriorly from the canine area to the molar regions, bilaterally; face page of the textbook where Bochdalek's report was published.

report 1) was hidden in ground more than 79 years. Despite this fact, the skull was found only slightly decalcified, no dozy and only slightly mechanically harmed. Unfortunately, there are no other bones from her body available. It is only known that she had two sisters and three brothers where no anomalies were reported. The process or re-examination of her skull was started using non-invasive CT method (iCATvision) in the lab of Department of Oral and Maxillofacial Surgery (detached workplace of the Stomatologic clinic, 1st Faculty of Medicine, Charles University, Prague) with the objective to survey intracranial abnormalities in the structure of Margaretha's skull (Fig. 1). This method helps us to describe internal structures without damaging fragile bones. Cross sections through skull, 3D reconstructions of the facial skeleton and detailed photos (made from the sloping side-face view) were made, too (Fig. 2).

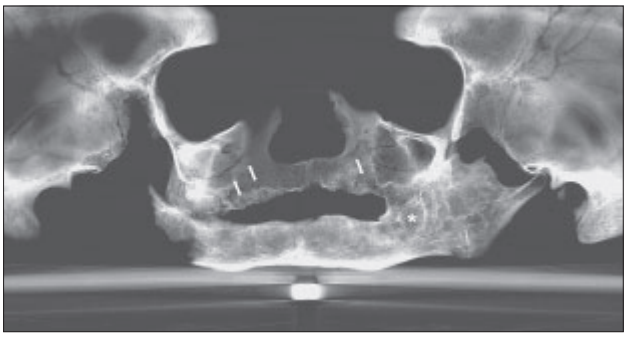

Fig. 3. Orthopanoramic view of this skull; thick arrows – cavities inside alveolar crest; thin arrow – compact bone surrounds mandibular canal (iCATvision).

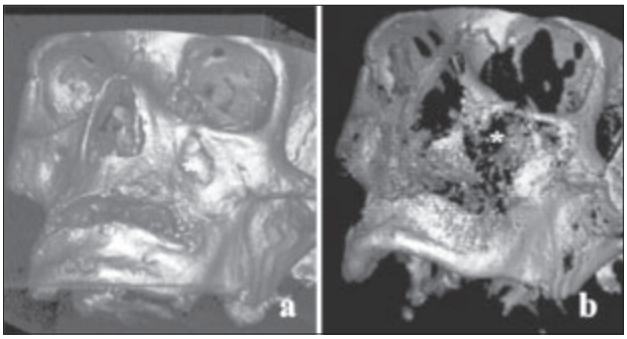

Fig. 4a, b. 3D reconstruction of the skull; semiaxial view; arrow – oval impact-like depression below distal orbital margine (iCATvision – Dolphin3D, 3DVR) a – 3D reconstruction of the facial skeleton surface; b – 3D reconstruction of the layer 2 mm below skull surface.

CT panoramic view reveals well conserved intraosseous trabecular system inside facial bones. Maxillary sinuses are sharply bordered and their alveolar and frontal recesses are empty. Numerous separated alveoli can be recognized in maxilla (thick arrows); large translucent area corresponding to molar alveolar space is seen in the lateral region of mandible (asterisk). Mandibular canal is sharply marginated (thin arrow) with thin compact bone (Fig. 3). No teeth primordia can be seen.

Slight discontinuity of the right inferior orbital marginae (Fig. 4a) and subconvexities directed up of both the inferior orbital margins are detected; a shallow drop-like depression is clearly seen at the site of the infraorbital foramen (Figs 4a, 5.). Bottom of this depression is composed from spongy and poorly calcified bone. (Fig. 4b).

Anti-mongoloid positions of both the orbital cavities, wide fronto-zygomatic suture on left side and deformity of the piriform aperture result in skull asymmetry and together with

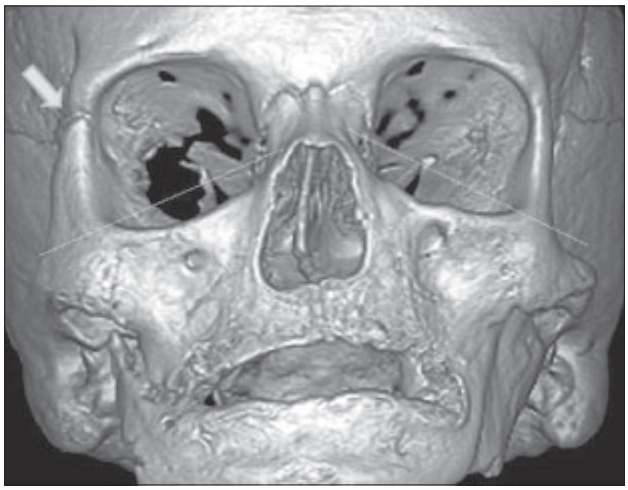

Fig. 5. 3D reconstruction of the skull, ventral view; arrow – wide groove at place of left frontozygomatic suture; lines – graphic illustration of the antimongoloid position of both the orbital cavities (iCATvision – 3DVR).

slightly protruded mandible causing facial skeleton relatively flat (Fig. 5).

No obliteration of the labyrinthic canals and tympanic cavities can be found; temporomandibular joint cavities are empty and contours of condyles continous are seen continuous. No osteophytic deformities can be observed inside mandibular fossae (Fig. 6a, b, c.). Remains of the alveolar cavities are recognized in CT sagittal sections; dorsal and ventral margins of empty alveoli in the frontal tooth region fuse together forming mound-like alveolar crests which are bent ventrally (Figs 5, 7). Inside the area of osseous fusion a thin layer of spongy bone can be determined (Fig. 8).

There is a heavy asymmetry between left and right halves of the facial skeleton with slight depressions below inferior orbital margins; mostly on the right side. Left ramus of mandible, palatine bone and zygomatic bone are closely connected by osseous trabeculae. Both maxillary sinuses are empty, and their recesses are demarcated by thin and continuous cortical bone layer. Osseous trabeculae in the bones are sharply seen without signs of their interruption. All teeth are completely absent but some empty alveoli mostly in frontal jaw segments are still present. Further, lower orbital margin in left side is found slightly waved closely above the infraorbital canal.

Atrophy of dorsal margins of palatine processes of both the maxillae can be detected. About two thirds of the hard palate are absent on the right side; but remnants of sutures between palatal processes of maxilla and palate bone can be clearly seen. There are no signs of post-inflammatory changes like trabecular deformities (Fig. 9).

Discussion

The tissue connecting mandible and maxilla in syngnathia malformation is mostly fibrous and osseous (6, 9, 11, 17), and even epithelial (30) with very different etiologies. Soft tissue fusions (8, 20) (synecchiae) have been extensively reviewed by Gartlan et al (1993) and were classified as buccopharyngeal membrane remnants or as ectopic membranes on the basis of their presumed origin (21). Bony fusion (syngnathia) where spongy as well as compact bone is developed in line of fusion is extremely rare. Some cases reported in the literature are mostly inadequate in description, their nomenclature is confusing and inconsistent and conventional imaging is made generally with limited facts (12, 13, 14, 22). There is high rate of association between bony syngnathia and other regional and systemic malformations (2, 13, 23, 24). High resolution radiography or spiral CT scan can showthe morphology of TM joints, the cavities of them are often hypoplastic or closed, and of hypoplastic changes in other skull bones. In this case report nothing from the above mentioned was confirmed. All bones in the presented facial skeleton are easily detected and their trabecular structures are clearly recognized. Mandible is fully developed. It is highly probable that deformities of both the infraorbital margins and waved surfaces of both maxillae can be caused by ongoing pressure of the growing mandibular rami and coronoid processes against facial skeleton after fusion between mandible, zygomatic bone and

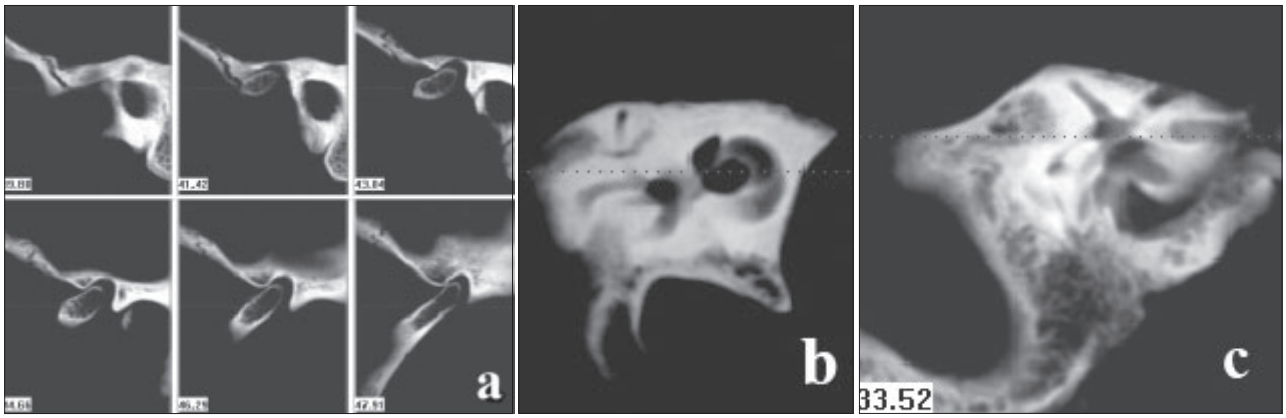

Fig. 6a, b, c. Sagittal sections through temporomandibular joints (TMJ) and through inner ear cavities; a – upper row – right TMJ, lower row – left TMJ; b – left osseous labyrinth with semicircular canals; c – right osseous labyrinth with semicircular canals (iCATvision, 3DVR).

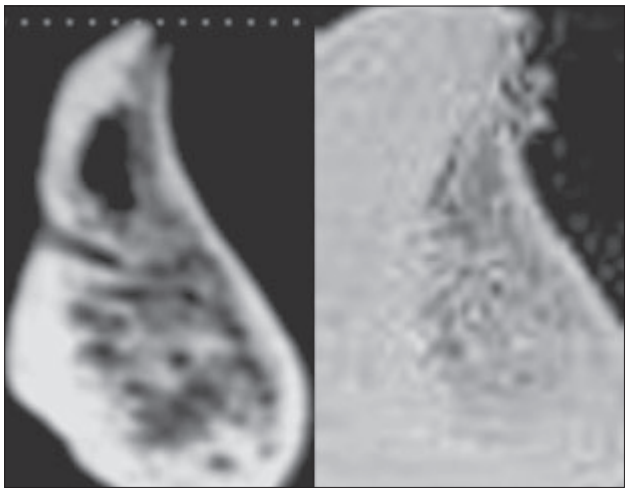

Fig. 7. Para median section through chin region exhibits nutritional canal below bottom of the incisal alveolus; left picture – part of its cavity is still present (irregular dark area); right picture – median section through interincisal septum; alveolar margines are fused and bent ventrally (iCATvision, 3DVR).

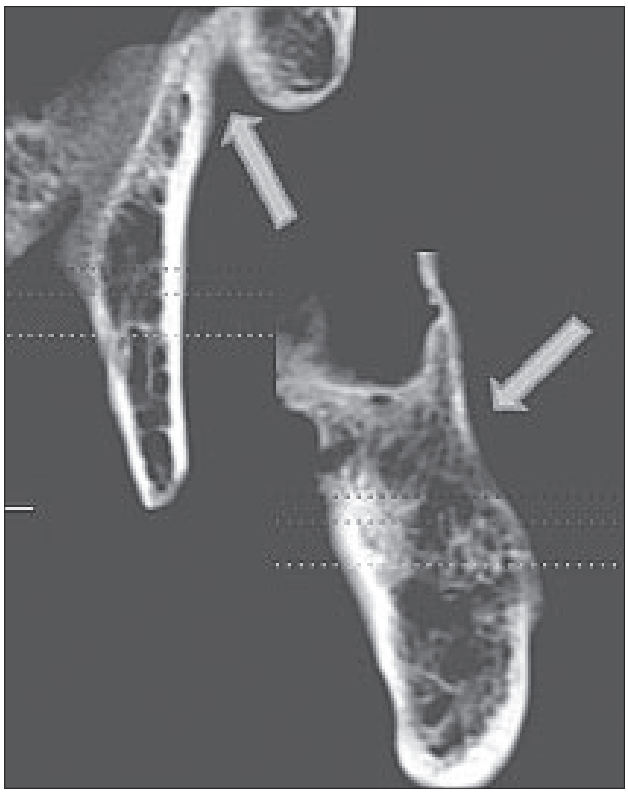

Fig. 8. Sagittal sections through vision area on the right side reveal compact bone connecting mandibule ramus and zygomatic bone (upper left picture); between mandibule and dorsal part of maxilla compact even spongy osseous tissue can be seen (lower right picture) (iCATvision, 3DVR).

maxillary tuberosities. Trends in enlargement of maxilla and mandible growth are well documented in papers of Enlow (25), Enlow et Hunter (26) and Cevidanes and coworkers (27, 28).

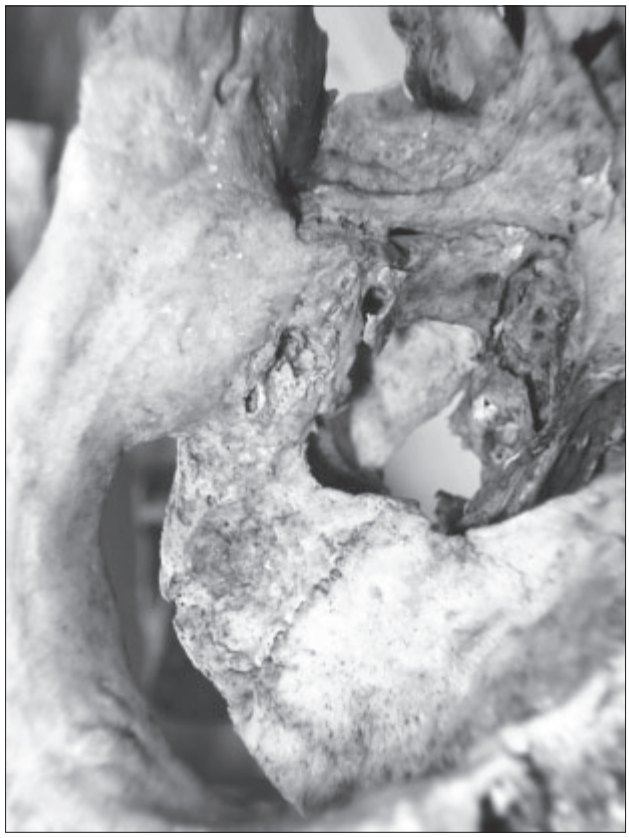

Fig. 9. Right part of the hard palate is atrophic; palatal bone is deformed and numerous osteophytic processes are seen. Notice of the median palatal suture. Dorsal margines of the palatine processes are blunt and rounded. No signs of the inflammatory changes (iCATvision, 3DVR).

Further, based on their observations it can be supposed that developmental disruptions of maxilla, if any, are usually followed by hypoplastic changes of mandible. This condition is repeatedly seen in autosomal recessive hypomandibular craniofacial dysostoses (12, 29). Nothing like this is observed in the examined skull. The median palatine suture is closed in ventral two thirds of hard palate. No cleft palate was detected. Massive loose of the palatine tissue in dorsal third of the hard palate (more on left side; see Figs 6a, b, c, 8.) can be explained with high credibility as a consequence of mechanical pressures due to a normal growth of tongue.

It is also believed that some drug or toxin influences reported by some authors (12, 15, 16, 18) can be calculated with higher security if significant hypoplastic and regressive changes in bone structures are found. Contradictory to this, no degenerative or postinflammatory signs were observed on flat skull bones. All bones are clearly detectable and their anatomic landmarks correspond to physiological ones typical for prepubertal age.

It is generally accepted that tongue growth influences formation of palatal shelves. In our case the oral cavity is too small, and there is no mobility of mandible firmly fused with skull base. No space for normal enlargement of tongue body exists and palatine processes are found incomplete. Following this nasal and

oral cavities are widely connected. Even lateral deviation of perpendicular plate of palatal bones and laterally deviated pterygoid processes can be considered as other credible proofs indicating of a pressure of growing tongue on bones. Important fact is that no hypoplastic and regressive changes are found in other skull parts which are sensitive to developmental disruptions like temporal complex, occipital bone and calvaria. This is why we prefer more mechanical than congenital pathogenesis of this malformation. This is our hypothesis of the development of this anomaly:

Due to some non-specified mechanical trauma wounded periosteal structures had undergone mutual fusion – first on the left side of facial skeleton. An ongoing development and growth of mandible had exerted a pressure on the midfacial components. This is why other face deformities like as bilateral asymmetry, waved infraorbital margins, disturbancies in external form of the facial bones and wide frontozygomatic suture were step by step developed. Loose of deciduous and permanent teeth could be a logic consequence. Numerous remnants of alveolar cavities are seen on CT scans. It can be supposed that some of teeth were removed iatrogenically following an endeavor to preserve oral cavity open. Ventrally bent alveolar walls and missing dorsal parts of hard palate (also mainly on left side) without signs of congenital cleft palate and laterally curved pterygoid processes can be explained also as an influence of the tongue growth and movement. Thus, it seems that malformation of facial skeleton was caused by unspecified mechanical trauma in very early age, when lower jaw, both upper jaws and zygomatic bones were pushed against each other.

Conclusion

Our report presents a case of bony syngnathia with bilateral vision where mandible, maxilla, zygomatic and palatal bones are mutually connected and malformed in forms.

We have pointed our findings (accepting original Bochdalek's diagnosis of bilateral syngnathia) in relation to the method used for examination as follows:

– syngnathia: osseous on right side; fibrous on left side) (Photo, CT3D reconstructions: maxilla, mandible, zygomatic bone and palate bone are mutually connected; right inferior orbital margine is slightly deflected cranially; sharply bordered depression below this margine is seen).
– atrophic deformity of the hard palate (CT: maxillary sinuses are empty and sharply bordered).
– asymmetric facial skeleton (Photo, CT: wider right frontozygomatic suture than the left one; anti-mongoloid position of both orbits).
– jaw deformities + osteophytes and osteoporotic areas in maxilla and mandible; sharply bordered trabeculae are crossing the area of the bone fusion.

Based on CT findings it seems to be presumed that mechanical trauma of the facial skeleton could trigger the activation of remodeling processes in bones resulting in presented skull deformity. Presented malformations can be considered as a consequence of numerous irritations of the facial skeleton in very young age.

References

1. Bochdalek VA. Beschreibung einer merkwürdigen Synostose des Unterkiefers mit beiden Oberkiefern (Syngnathia) als Beitrag zur pathologischen Anatomie der Knochen. Eds. Halla J, Hasner JR. Vierteljahrschrift für die Praktische Heilkunde. Zweiter Band. Verlag von Carl Reichenecker. 1871.

2. Mushtaq AM, Iqbal S, Adil H, Zargar HR, Rasool A, Mohsin M, Darzi A. Syngnathia without any other associated anomaly: a very rare case report. Internet J Plast Surg 2009; 1528—8293.

3. Laster Z, Temkin D, Zarfin Y, Kushnir A. Complete bony fusion of the mandible to the zygomatic complex and maxillary tuberosity: case report and review. Int J Oral Maxillofac Surg 2001; 30 (1): 75—79.

4. Daniels JS. Congenital maxillomandibular fusion. A case report and review of the literature. J Craniomaxillofac Surg 2004; 32 (3): 135—139.

5. Dawson KH, Gruss JS, Myall RW. Congenital bony syngnathia. A proposed classification. Cleft Palate Craniofac J 1997; 2: 141—146.

6. Trigg DJ, Mau IT, Rosbe KW. Complete bony syngnathia: Report of a case and review. Arch Otolaryngol Head Neck Surg 2007; 133 (2): 187—190.

7. Ugurlu Karsidags, Huthul I, Yildiz K.Bas. Congenital fusion of maxilla and mandible: Brief clinical note. J Craniofacial Surg 2005; 16 (2): 287—291.

8. Dawson KH, Gruss JS, Myall RW. Congenital bony syngnathia. A proposed classification. Cleft Palate Craniofac J 1997; 2: 141—146.

9. Simpson JR, Maves MD. Congenital syngnathia or fusion of the gums and jaws. Otol Head Neck Surg 1985; 93: 96—99.

10. Trigg DJ, Mau IT, Rosbe KW. Complete bony syngnathia: Report of a case and review. Arch Otolaryngol Head Neck Surg 2007; 133 (2): 187—190.

11. Gahm C, Kuylenstierna R, Papatziamos G. Popliteal pterygium syndrome (PPS) with intra-alveolar syngnathia: A discussion of anesthetic and surgical considerations. Int J Pediatr Otorhinolaryngol 2007; 71 (10): 1613—1616.

12. Rao S, Oak S, Wagh S, Kulkarni M. Congenital midline palatomandibulart bony fusion with mandibular cleft and a bifid tongue. Brit J Plast Surg 1977; 50: 139—141.

13. Miskinyar SA. Congenital mandibulomaxillary fusion. Plast Reconstr Surg 1979; 63: 120—121.

14. Nwoku AL, Kekere-Ekun TA. Congenital ankylosis of the mandible. J Maxillofac Surg 1986; 14: 150—152.

15. Kamata S, Satoh, Vemura T, Onizuka T. Congenital bilateral zygomaticomandibular fusion with mandibular hypoplasia. Brit J Plast Surg 1996; 49: 251—253.

16. Goodacre TE, Wallace AF. Congenital alveolar fusion. Brit J Plast Surg 1990; 43: 203—209.

17. Shah RM. Palatomandibular and maxillo-mandibular fusion, partial aglossia and cleft palate in a human embryo. Report of a case. Teratology 1977; 15: 261—272.

18. Nada R. Maxillomandibular ankylosis and cleft palate in rat embryos. J Dent Res 1970; 49: 1086—1090.

19. Gorlin J, Cohen M, Michael, Levin L, Stefan. Syndromes of Hand and Neck. 3rd ed. England: Oxford University Press; 1990: 630-1, 783.

20. Dinardo NM, Christion JM, Benneth JA, Shutack JG. Cleft palate lateral synechia syndrome. Oral Surg Oral Med Oral Pathol 1989; 68: 565—566.

21. Kamala G, Pillai V, Kamath V, Kumar GS, Nagamani N. Persistent buccopharyngeal membrane with cleft palate. Oral Surg Oral Med Oral Pathol 1990; 69: 164—166.

22. Johnsson GF, Robinow M. Aglossia-adactylia. Radiology 1978; 128: 127—132.

23. Behnia H, Shamse MG. Congenital unilateral fusion of the mandibular and maxillary alveolar ridge, tempo romandibular joint, and coronoid process. J Oral Maxillofac Surg 1996; 54: 773—776.

24. Agarwal K, Chandra SS, Sreekumar NS. Congenital bilateral intermaxillary bony fusion. Ann Plast Surg 1993; 30: 163—166.

25. Enlow DH. A morphogenetic analysis of facial growth. Amer J Orthop 1966; 52 (4): 283—299.

26. Enlow DH, Hunter WS. A differential analysis of sutural and remodeling growth in the human face. Amer J Orthop 1966; 52 (11): 823—830.

27. Cevidanes LH, Franco AA, Gerig G, Proffit WR, Slice DE, Enlow DH, Yamashita HK, Kim YJ, Scanavini MA, Vigorito JW. Assessment of mandibular growth and response to orthopedic treatment with 3-dimensional imaging. Amer J Orthop Dentofacial Orthop 2005; 128 (1): 16—26.

28. Cevidanes LH, Franco AA, Gerig G, Proffit WR, Slice DE, Enlow DH, Lederman HM, Amorim L, Scanavini MA, Vigorito JW. Comparison of relative mandibular growth vectors with high-resolution 3-dimensional imaging. Amer J Orthop Dentofacial Orthop 2005; 128 (1): 27—34.

29. Nada R. Maxillomandibular ankylosis and cleft palate in rat embryos. J Dent Res 1970; 49: 1086—1090.

30. Puvabanditsin S, Garrow E, Sitburana O, Avila FM, Nabong MY, Biswas A. Uber zwei Falle epithelialer Syngnathie bei menslichen Keimlingen. Paperback 2003; 40 (1): 104—106.

31. Watatani S, Eguchi T, Hikiji H, Susami T, Takato T, Komori T. A case of syngnathia with cleft palate. Jap J Oral Maxillofac Surg 2002; 48 (9): 467—470.

32. Cech P, Kachlik D. 175'th anniversary of Bochdalek's inaugural dissertation. Biomed Pap Med Fac Univ Palacky Olomouc Czech Repub 2009; 153 (1): 1—4.

Received May 27, 2009.
Accepted September 20, 2009.