Bratisl Lek Listy 2009; 110 (7)
419 – 422

CLINICAL STUDY

The effect of photocoagulation on visual acuity in diabetic patients suffering from diabetic macular edema and diabetic retinopathy

Ilavska M

Ophtalmology Ward St. Lucas Hospital, Galanta, Slovakia. **ilavsky.m@stonline.sk**

Abstract: *The aim of the study* was to evaluate the effect of photocoagulation and range of treatment on visual acuity (VA) in patients with diabetic macular edema.
Material and method: 56 patients with type II diabetes mellitus – 109 eyes were divided into four groups depending on the type of treatment. The evidence of macular edema based on biomicroscopic evaluation or fluorescein angiography was the criterion of the need to start with photocoagulation. VA was evaluated every 6 months up to 3 years after the treatment.
Results: In the first group, 54 eyes were treated by focal photocoagulation. VA was stabilized in 45 (83.3 %), improved in 3 (5.6 %), and in 6 (11.1 %) eyes became worse. In the second group, 7 eyes were treated by grid photocoagulation. VA was stabilized in 6 (85.7 %) eyes, and 1 (14.3 %) eye got worse. In the third group, 29 eyes were treated with combination of the direct treatment in macular region with panretinal photocoagulation (PRP). In the latter group, VA was stabilized in 22 (75.9 %) eyes, improved in 3 (10.3 %), and in 4 (13.8 %) eyes it got worse. In the fourth group, 19 eyes were treated with a combination of grid photocoagulation and PRP. VA was stabilized in 16 (84.2 %), improved in 2 (10.5 %) eyes, and got worse in 1 (5.3 %) eye.
Conclusion: Results of this study affirm the benefit of photocoagulation for keeping the visual acuity. Reasonable range and correct timing of treatment are indispensable *(Fig. 6, Tab. 2, Ref. 21).* Full Text (Free, PDF) *www.bmj.sk.*
Key words: diabetic maculopathy, photocoagulation, visual acuity.

Diabetic retinopathy is a late complication of diabetes mellitus. There are two causes for vision deterioration or blindness – diabetic maculopathy and complications accompanying the origin and the development of diabetic retinopathy (DR) (15).

The accumulation of fluid in nerve fiber layer and inner nuclear layer of retina due to disruption of inner haematoretinal barrier causes the diabetic macular edema.

Fluid and macromolecules from plasma pass from intravascular to extravascular space. These changes bring about an accumulation of hard exudates. The hard exudates are primarily accumulated in inner and outer plexiform layers; i.e. in deeper parts of retina during final stages of disease. The presence of hard exudates is accompanied by degeneration of photoreceptors. Retinal pigment epithelium becomes irregular. This haematoretinal external barrier provides balance to fluid transport in retina. The general status is important, namely hypertension, cardial or renal insufficiency, dislipidemia and fatness (6, 8, 14, 19, 20, 21).

Ophtalmology Ward St. Lucas Hospital, Galanta, Slovakia

Address for correspondence: M. Ilavska, MD, Ophtalmology Ward St. Lucas Hospital, Hodska 373/38, SK.924 22 Galanta, Slovakia.

Acknowledgments: The author thanks the physician and the staff of Ophtalmology Ward at St. Lucas Hospital Galanta for support in this study, as well as Marian Potocky Doc, MD, PhD and Ján Jakubovský Prof, MD, CSc who provided consultation and reviewed the project.

The edema can occur as focal or diffuse. The ischemic maculopathy has poor prognosis; it is based on areas of non-perfusion.

The focal edema reveals with the rapid and diffuse leakage of the contrast substance (fluorescein) from capilaries. Good capillary perfusion is present on fluorescein angiography (FA). Diffuse edema reveals with diffuse leakage of fluorescein from huge areas of capillary network in the posterior pool. The cystic spaces are filling with fluorescein at the area of cystoid macular edema. The areas of non-perfusion are present in the area of ischemic maculopathy (1, 19).

Retinal findings in FA improve the accuracy and the range of photocoagulation (1, 8, 9, 11, 16). The benefit of photocoagulation is in the increasing of oxygenation of retina, improvement in hemodynamics and transport of fluid in retina (3, 7).

The aim of the study is to evaluate the effect of treatment by photocoagulation in patients with diabetic macular edema. The study is based on the comparison of central visual acuity before and after the photocoagulation.

Methods

The group of 56 patients with type II diabetes mellitus was evaluated in a retrospective study. 109 eyes were treated with photocoagulation for macular edema. The time from the start of

Tab. 1. Groups of eyes according the type of photocoagulation.

Type of photocoagulation	Number of eyes	%
Focal photocoagulation	54	49.54
Grid photocoagulation	7	6.42
Focal photocoagulation and PRP	29	26.61
Grid photocoagulation and PRP	19	17.43
Total	109	100

Tab. 2. Visual acuity after photocoagulation.

Characteristics of photocoagulation	VA stabilised	VA improved	VA worsed
focal	45 (83 %)	3 (5.6 %)	6 (11 %)
grid	6 (85.7 %)	0	1 (14.3 %)
focal + PRP	22 (75.9 %)	3 (10.3 %)	4 (13.8 %)
grid + PRP	16 (84.2 %)	2 (10.5 %)	1 (5.3 %)

photocoagulation varied from six months to three years. The evidence of macular edema based on biomicroscopic evaluation or fluorescein angiography was the criterion for starting with photocoagulation. In case of focal macular edema, leaking microaneurysms (MA) were present on FA. A clinically significant macular edema, which is the criterion for starting with photocoagulation is characterised by the following signs:

– thickening of the retina at or within 500 microns of the center of the macula,
– hard exudates in this region, if associated with thickening of adjacent retinae,
– a zone or zones of retinal thickening 1 disc area or larger, any part of which is within 1 disc diameter of the center of macula.

The focal photocoagulation of leaking MA was done for the first time in treatment of nonproliferative diabetic retinopathy (NPDR), in distance of 1000 um from the centre and farther. The argon – green laser burns of 100 microns (514 nm) were used with duration of 0.1 s or less, with adequate power to obtain whitening or darkening of MA. The areas of diffuse leakage or nonperfusion at nonproliferative DR were treated in the grid pattern. The burns in size of 200 microns were placed 500 to 3000 microns from the center of macula. The goal of treatment is to produce a burn of light to moderate the intensity. Sequence panretinal photocoagulation (PRP) was done in patients with severe NPDR or proliferative diabetic retinopathy (PDR). Blue-green laser of 488 nm, burns of 200–300 microns, duration of 0.1 s were used to obtain light whitening of retina.

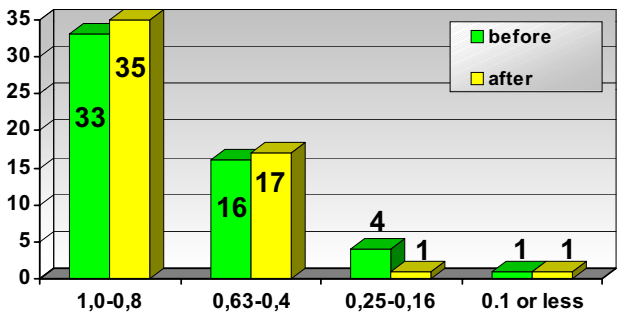

Fig. 1. VA before and after focal photocoagulation of diabetic macular edema.

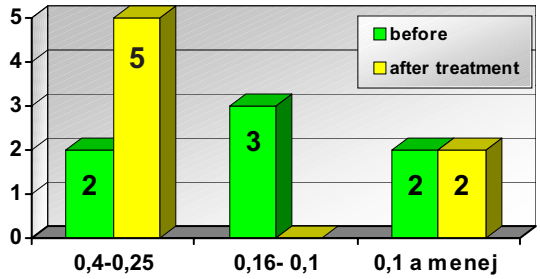

Fig. 2. VA before and after grid photocoagulation of diffuse macular edema.

Results

The group of 109 eyes, 56 patients, was divided to 4 groups according to the type of photocoagulation (Tab. 1). Visual acuity (VA) was evaluated before and after the treatment on Snellen optotypes. Change in VA by one line was regarded as stabilization. Improvement or worsening of VA was considered when VA was changed by 2 or more lines of optotypes. Table 2 shows VA before and after the treatment categorized according to type of photocoagulation.

The first group, i.e. 54 eyes with nonproliferative diabetic retinopathy (NPDR), with clinically significant macular edema, was treated by focal photocoagulation. The VA was stabilized in 45 (83.3 %), improved in 3 (5.6 %) and deteriorated in (11.1 %) eyes. 33 eyes had VA of 1.0–0.8 before treatment, and 35 eyes after the treatment. VA of 0.63–0.4 before treatment was present in 17 eyes. VA less than 0.25 was present in 5 eyes.

In the second group, 7 eyes with NPDR with diffuse macular edema were treated with grid photocoagulation. VA was stabilized in 6 (5.7 %) eyes and deteriorated in 1 (14.3 %) eye. In this group, VA of 0.4–0.25 before treatment was in 2 eyes, after the treatment in 5 eyes. 2 eyes with VA of 0.1–0.16 got better to 0.4–0.25. 2 patients had VA of 0.1 or less before and after the treatment.

In the third group, 29 eyes treated for severe NPDR with clinically significant macular edema were treated with a combination of focal and panretinal photocoagulations. 22 eyes (75.9 %) were stabilized, 3 (10.3 %) eyes were improved and 4 (13.8 %) eyes deteriorated. 19 eyes had VA 1.0–0.8 before as well as after the photocoagulation. VA of 0.63–0.4 before treatment was present in 8 eyes, and after treatment, in 6 eyes. VA of 0.1 or less was present in 2 eyes.

In the fourth group, 19 eyes with severe NPDR or PDR with diffuse macular edema were treated with a combination of grid

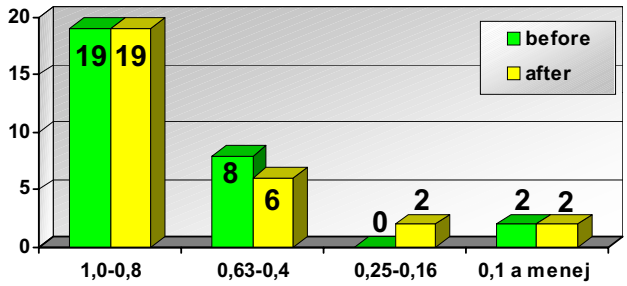

Fig. 3. VA before and after focal photocoagulation for focal diabetic macular edema and PRP for severe diabetic retinopathy.

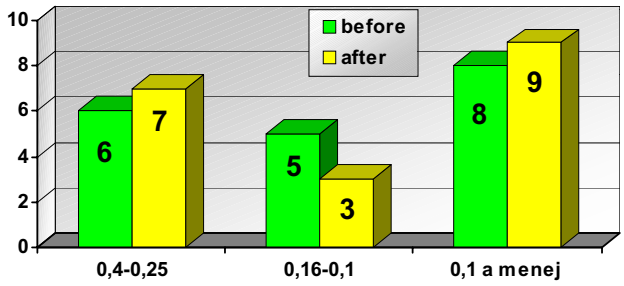

Fig. 4. VA before and after grid photocoagulation for diffuse macular edema and PRP for severe diabetic retinopathy.

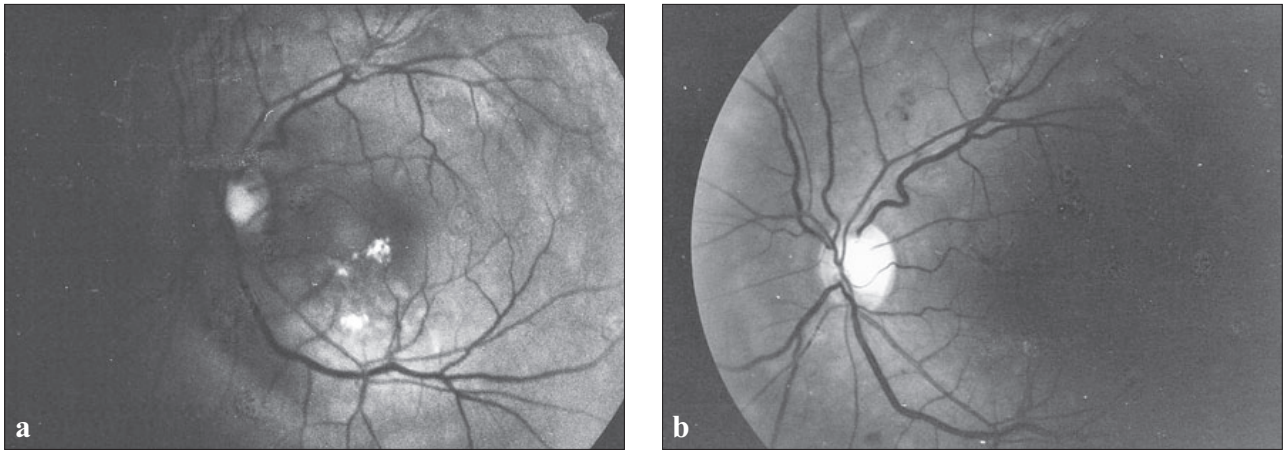

Fig. 5. Hard exudates at clinically significant macular edema. a) before photocoagulation, b) disappearance of hard exudates six months after photocoagulation.

and panretinal photocoagulations. VA was stabilized in 16 eyes (84.2 %), improved in 2 eyes (10.5 %) and one eye (5.3 %) got worse. VA in this group was 0.4 or less. Figure 1–4 shows changes in VA in these four groups.

Disappearance of hard exudates was recorded after the laser treatment. Figures 5 a and b shows hard exudates before and six month after the focal treatment of the macular edema.

Discussion

Diabetic maculopathy remains a permanent therapeutic and social problem despite advances in the therapy of diabetes mellitus. Previous studies suggested that photocoagulation might be beneficial in the treatment of diabetic macular edema (1, 3, 4, 5, 12, 15, 16, 18). Results of this study can confirm these findings. When deciding whether to use photocoagulation it is necessary to consider some factors in respect of the development and prognosis of macular edema. A clinically significant macular edema based on biomicroscopic evaluation and the risks of VA deterioration are indications for laser treatment (13, 16).

In the first group, the focal photocoagulation was done in patients with NPDR with clinically significant macular edema. There were patients with good VA, in whom retinal changes were endangering the center of macula. VA was stabilized in 45 (83.3 %), improved in 3 (5.6 %), and in 6 (11.1 %) eyes it became worse. A deterioration by more than 3 lines did not occur. Boguszakova et al reached stabilisation in 62.2 % of patients, and improvement in 28.9 % of patients (1). Řehak et al observed stabilisation in 77 % of patients, improvement in 17 %, and worsening of VA in 6 % of patients in two years following focal photocoagulation (16). Early Treatment Diabetic Retinopathy Study presents stabilisation in 65 % patients 1 year after the focal treatment despite the worsening in 63 % patients who were not treated (3). The disappearance of hard exsudates was recognised in our group of patients after the focal laser treatment. This condition remains stabilized after 3 following years (Fig. 5 a, b).

The results achieved in the second group correlate with advanced changes in macular region. These findings confirm that long-term edema damages the photoreceptors, and causes dystrophic changes in retinal pigment epithelium. This is the cause of permanent deterioration of visual acuity. Dystrophic changes in central macula must be differentiated from other etiologies, for example age-related macular degeneration.(15) In case of diffuse macular edema, panretinal photocoagulation was needed frequently. Stabilisation of VA was recorded in 6 (85 %) eyes and deterioration in 1 eye (14.3 %). Stefaniotou et al demon-

strate the favourable effect of grid photocoagulation on the diffuse macular edema (18). Stabilisation in 74 % and improvement in 20 % after one-year follow-up is described in the study of Olk and co-authors (13). Boguszakova illustrates stabilisation of diffuse edema in 37 % and improvement in 29.6 % of patients (1).

In the third group of 9 eyes with NPDR with clinically significant macular edema treated with combination of focal and panretinal photocoagulation, stabilisation was achieved in 22 (75.9 %) eyes, improvement in 3 (10.3 %) and deterioration in 4 (13.8 %) eyes. VA at the start of treatment was 1.0–0.8. No worsening by 3 or more lines occured. These outcomes confirm the results of EDTRS study, which demonstrates the favourable impact of focal fotogoaulation of macular region in patients in need of PRP (3).

The fourth group of 19 eyes with severe NPDR or PDR with diffuse macular edema was treated by grid and panretinal photocoagulation. The initial VA was 0.4 or less. Stabilisation of VA was achieved in 16 (84.3 %) eyes, improvement in 2 eyes (10.5 %), and one eye got worse. The severity of diabetic retinopathy reflects the duration and compensation of diabetes mellitus. The Wisconsin Epidemiologic Study of Diabetic Retinopathy demonstrates the effects of age, type and duration of diabetes mellitus, level of hyperglycemia (measured by glycosylated haemoglobin), blood pressure and proteinuria (2, 9, 13).

The implication of this finding is as follows:

1) Focal treatment can stabilize VA.
2) Photocoagulation in early stage maintains the initial VA.
3) Regular examinations of diabetic patients are crucial. Intervals between controls should shorten with the duration of diabetes mellitus in order to survey the early stages of diabetic retinopathy.
4) VA does not improve significantly after the resolution of several diffuse macular edemas.

Conclusion

The results of presented collection of patients show a favourable influence of photocoagulation on preservation of visual acuity providing the range is sufficient and timing correct. The biomicroscopic evaluation and the fluorescein angiography are appropriate indicators of the need to start with therapy. FA is suitable also for the monitoring of the success of therapy. Macular edema advances slowly, but early treatment is effective against loss of vision. The aim of photocoagulation is to preserve the visual acuity recorded at the beginning of therapy. Good compensation of diabetes mellitus (controlled by the level of glycosylated haemoglobin), treatment of primary diseases as hypertension and hyperlipidemia are crucial for long-term stabilization of diabetic maculopathy. Glycemia and hypertension were treated by an internist and they were not assessed in the group characteristics of patients.

References

1. Boguszaková J, Doležalová J, Gajdošíková Z, Havlíková M. Diabetická makulopatie. Čs Oftal 1994; 50: S12—18.

2. British Multicentre Study Group: Photocoagulation for Diabetic Maculopathy. Diabetes 1983; 32: 1010—1016.

3. Early Treatment Diabetic Retinopathy Study Research Group: Photocoagulation for Diabetic Macular Edema. Arch Ophtalmol 1985; 103: 1796—1806.

4. Early Treatment Diabetic Retinopathy Study Research Group: Treatment techniques and Clinical Guidelines for Photocoagulation of Diabetic Macular Edema. Ophtalmology 1987; 94: 761—774.

5. Hoerle S, Kroll P. Evidence-based therapy of diabetic retinopathy. Ophtalmologica 2007; 221 (2): 132—141.

6. Ino-ue M, Azumi A, Kajiura-Tsukahara Y, Yamamoto M. Ocular Ischemic Syndrome in Diabetic Patients. JpnJ Ophtalmol 1999; 43: 31—35.

7. Jeppesen P, Bek T. Impaired retinal autoregulation in small retinal arterioles before and after focal laser treatment for diabetic maculopathy. Brit J Ophtalmol 2006; 90 (2): 198—201.

8. Kalvodová B. Screening diabetické retinopatie v ČR — guideline. Čs Oftal 2002; 58: 3—10.

9. Kalvodová B, Oudová P. Screening diabetické makulopatie. Čs Oftal 2002; 58: 11—15.

10. Klein R, Moss SE, Klein BEK, Davis MD, DeMets DL. The Wisconsin epidemilogic study of diabetic retinopathy. XI. The incidence of Macular Edema. Ophtalmology 1988; 96: 1501—1510.

11. Kylstra JA, Brown JC, Jaffe GJ, Cx TA, Gallemore R, Greven CM, Hall JG, Eifrig DE. The importance of fluorescein angiography in Planning Laser Treatment od Diabetic Macular Edema. Ophtalmology 1999; 106: 2067—2073.

12. Meyer CH. Current Treatment Approaches in Diabetic Macular Edema. Ophtalmologica 2007; 221: 118—131.

13. Olk J. Modified Grid Argon (blue—green) Laser Photocoagulation for Diffuse Diabetic Macular Edema. Ophtalmology 1986; 93: 938—950.

14. Ponťuch P, Vozár J, Potocký M, Krahulec B. Relationship between nephrophaty, retinopathy and autonomic neuropathy in patiens with type 1 diabetes. J Diabet Complications 1990; 4: 188—192.

15. Rencová E, Havel E, Novák J, Zadák Z, Solichová D, Barátová M, Svěrák J, Hartmann M. Dystrofické zmeny pigmentového epitelu makuly jako následek exudativní diabetické makulopatie. Čs Oftal 1996; 52: 291—296.

16. Řehák J, Chrapek O, Prachařová Z, Gbelcová M. Naše zkušenosti v léčbě diabetické makulopatie. Čs Oftal 2004; 60: 112—117.

17. Schofield CJ, Ellis JD, Ellinford A, Morris AD, Leese GP. Macular oedema is not predicted by perifoveal single blot haemorrhages. Diabet Med 200; 25: (2): 129—133.

18. Stefaniotou M, Kalogeropoulos Ch, Psilas K. Long-term Visual Results after Photocoagulation for Diabetic maculopathy. Ophtalmologica 1995; 209: 64—67.

19. Tranos PG, Wickremasinghe SS, Stangos NT, Topuzois F, Tsinopoulos I, Pavesio CE. Macular Edema. Surv Oftalmol 2004; 49: 470—490.

20. Valešová L, Hycl J. Diabetická retinopatie. Praha; Triton, 2002, 15—41.

21. Potocký, M. Súčasné názory na patogenézu diabetickej retinopatie. Bratisl Lek Listy 1999; 100 (1): 67—68.

Received February 23, 2009.
Accepted March 12, 2009.