

CLINICAL STUDY

Osteoplastic static thumb replacement for the total traumatic thumb loss

Burda R, Kitka M

Department of Trauma Surgery, Faculty Hospital of Louis Pasteur, Kosice, Slovakia. burda@netkosice.sk

Abstract: Despite the fact that replantation of the thumb is at present a common procedure, occasionally due to the different reasons replantation is unsuccessful. We present a case where we have to cope with complete thenar loss and following reconstruction was done in an unusual way. Primarily we have covered the thenar defect with inguinal flap and secondarily we have made thumb bone replacement with heterogenous bone block fixed to the second metacarpal bone. We would like to point out that sometimes it is necessary to make reconstructions by unusual way (Fig. 7, Ref. 14). Full Text (Free, PDF) www.bmj.sk.

Key words: failed thumb replantation, thumb reconstruction, hand infection, vacuum assisted closure in septic hand.

Loss of the thumb significantly impairs hand function. Given this, reconstruction of an opposing thumb should be attempted whenever possible by using whatever technical means are available to the surgeon (1).

The overall survival of thumb replantation is generally high, reaching almost 90 %. Of the thumbs that were re-explored for vascular compromise, 75 % were successfully salvaged. However, the use of vein grafting seemed to be beneficial for the successful outcome of replantation in severe crush and avulsion injuries, even though the values did not reach statistical significance. Thumb replantation is associated with very high survival rate, regardless of the mechanism of injury or level of amputation, and should be attempted in all cases. An early reexploration for vascular problems yields a high salvage rate and should be performed in all cases (2).

Evaluation of the functional and subjective results after thumb replantation was done. Functional results were independent of amputation levels and patient age. Although the results of cutaneous sensibility are only moderate, patients are able to use their thumb to perform work and daily living activities. The majority of patients is returning back to their previous occupation (3).

Case report

A 56 year old worker injured his left non dominant hand by saw bar. During initial revision there was an uncovered subtotal

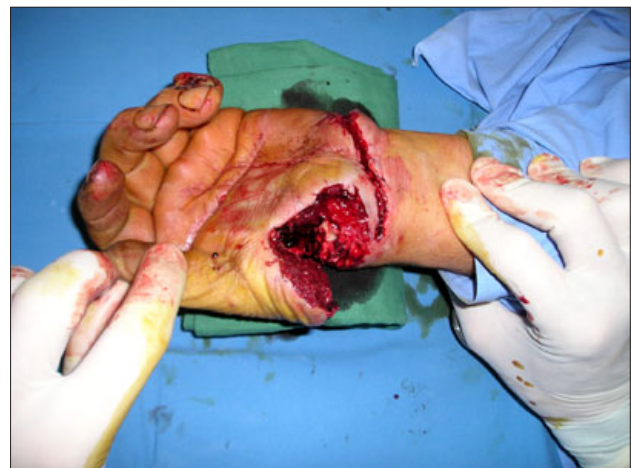

Fig. 1. Initial view of injury.

amputation of the thumb and thenar which presented itself by fully ischemic thenar and thumb. Skin bridge 4.5 cm wide was left on ulnar side of the thenar (Fig. 1). Concurrently there complete lesion of superficial and deep flexor tendons of second finger, ulnar artery and nerve were found. Ulnar artery was sutured end to end and subsequently ulnar nerve was repaired by epineural and perineural suture.

Thumb semi amputation line was oriented just through trapezio – scaphoideal joint. Provisional fixation was done by K-wire and consequently tendons and nerves were repaired. Principal pollux artery was sutured end to end without any tension and the anastomosis was fully functional. Finally both venous anastomoses were done. Thumb perfusion was adequate after the revascularization.

Department of Trauma Surgery, Faculty Hospital of Louis Pasteur, Kosice, Slovakia

Address for correspondence: R. Burda, MD, Dept of Trauma Surgery, Faculty Hospital of Louis Pasteur, Rastislavova 43, SK-040 80 Kosice, Slovakia.
Phone: 0903 883 323

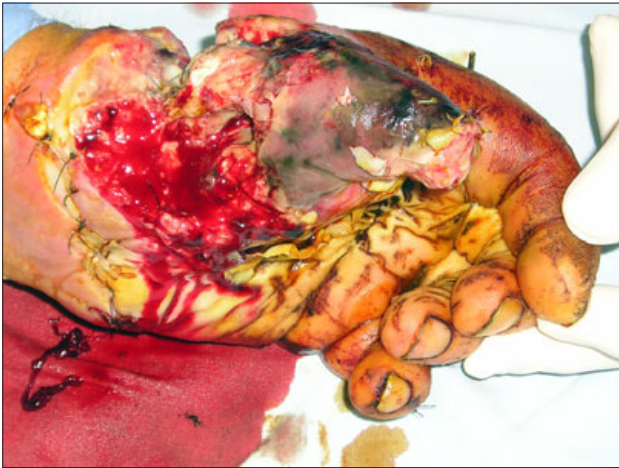


Fig. 2. Thenar and thumb necrosis after unsuccessful revascularisation.

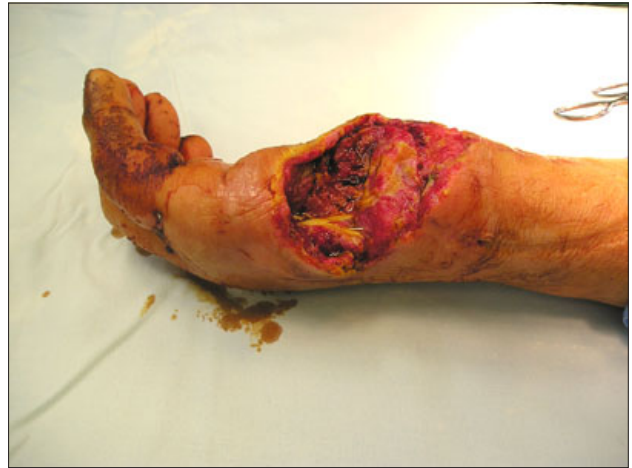


Fig. 3. Extent of hand defect.

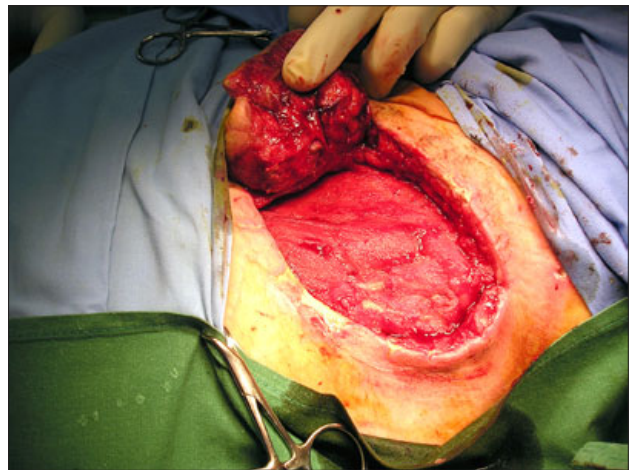
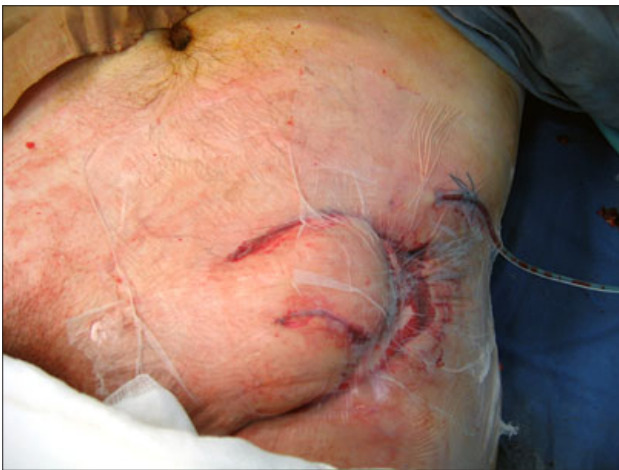

Fig. 4. A - VAC therapy for infected inguinal flap, B - state of inguinal flap after VAC therapy.

After 48 hours signs of arterial thrombosis were present. Revision has exposed extensive arterial thrombosis which was solved by venous bypass connecting proximal stump of principal pollux artery and distall end parts of the same artery just below the bifurcation. Bypass was also fully functional. After next 72 hours weak bleeding from proximal arterio-venous anasthosis occurred. Revision was done repeatedly and next stitch was added to the anasthosis. Signs of thrombosis have occurred after next 72 hours and concurrently suppuration appeared. During revision massive infection and necrosis of thenar muscles and also of subcutaneous tissue was apparent. Radical necrectomy was done and due to functional venous by-pass an attempt to save the thumb was made. Defect was covered with inguinal flap. We have preferred distant axial pattern flap because of high risk of failure of free flap due to the high risk of infection.

After 4 days signs of infections and necrosis occurred. Inguinal flap had to be detached (Fig. 2). Due to the mentioned findings and inflammation of neighbouring soft proximal tissues

complete amputation of the thumb and thenar was indispensable (Fig. 3). Infected inguinal flap and also extensive thenar defect was treated by VAC till signs of infection disappeared and tendency to heal occurred (Fig. 4, 4a). Because firm made sets for VAC therapy were not available, we had used sponge to fulfill the infected defect and vacuum was reached using the classical Redon drains inserted from the defect to the outside area. Subsequently the defect was covered with sterile folium.

The flap was than again tubularized and connected to hand defect. No further complications occurred. After three weeks the flap was detached. We have suggested toe finger transfer, but the patient refused this treatment modality. So we had to perform an unusual reconstruction and fulfill the flap with heterogeneous tricortical bone block which has to be fixed to the second metacarpal bone with 2 cortical screws (Figs 5, 6). It should not be fixed by another way because of complete loss of trapezium bone. After 3 month debulking procedure was performed. The patient has used protective orthosis. At the moment he is fully able of common work and refuses any another reconstruc-

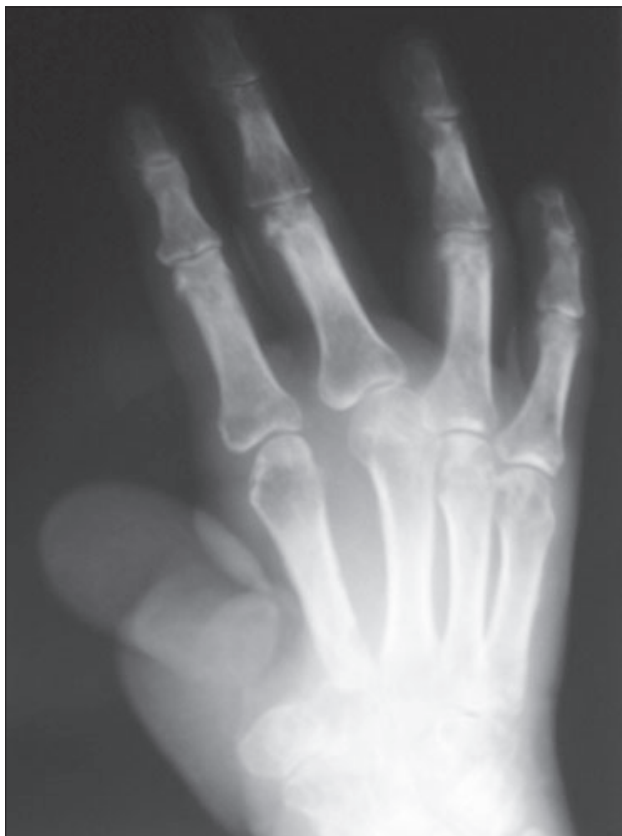

Fig. 5. PA view of hand before reconstruction.

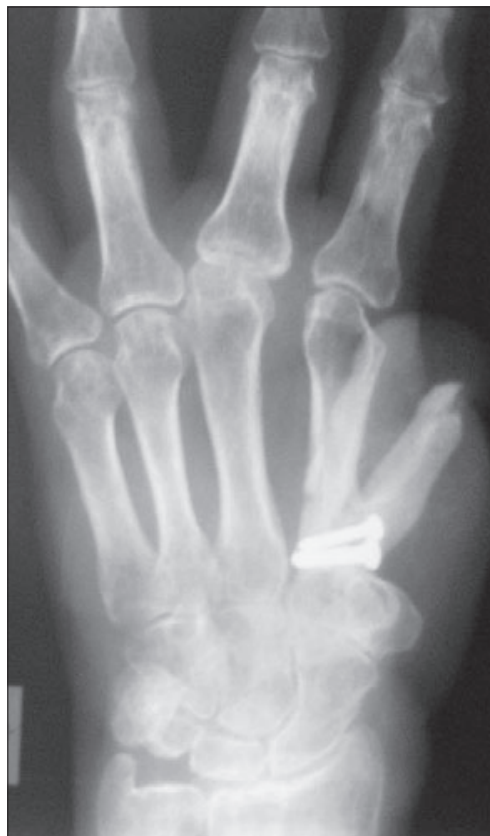

Fig. 6. PA view of hand after reconstruction.

tions. One year after reconstruction bone graft was unchanged in its sized and bone consolidation has occurred between bone graft and second metacarpal bone. At the moment the patient is fully able of normal living activities including not demanding work (Figs 7, 8).

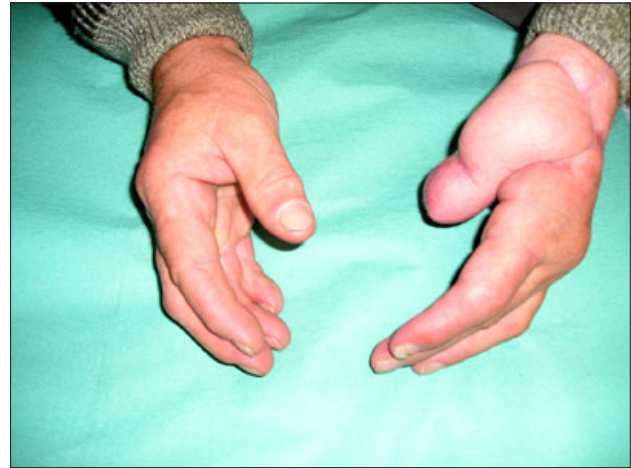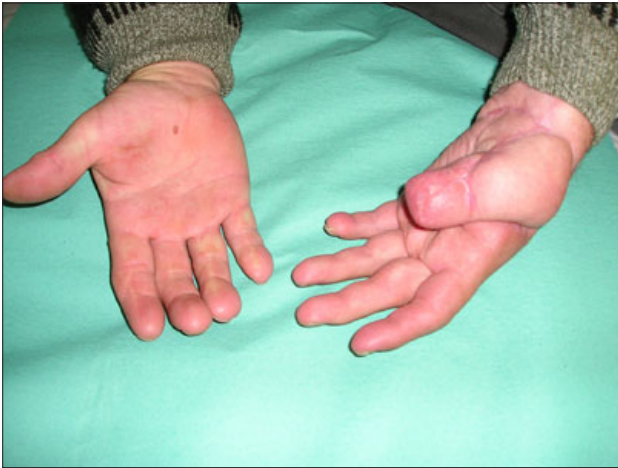Discussion and conclusion

The loss of a thumb is traumatic on the functional, cosmetic and psychological level. If immediate replantation can not be successfully accomplished, the surgeon must plan to treat the patient within the first days or, at the latest, within the first weeks following the injury. If the patient is left to "mourn" his lost thumb, he will find it difficult to incorporate his new thumb into his body image and this will compromise the results of a late reconstruction. There is a vast range of therapeutic options, even for cases of severe injury. The most classic treatments include lengthening the first metacarpal, osteoplasty, pollicization of long fingers or stump. These techniques were very common up until the late 1970's at which time microsurgical techniques of partial or total toe transfer became popular. For a short time, there was some opposition between proponents of classic techniques and microsurgions. In fact, there was a role for each method and classic and microsurgical techniques became complementary. Nowadays microsurgical techniques dominate in thumb recon-

structions. Very early on, it was decided against the use of the big toe because of the resulting plantar sequelae and preferred use of the second toe (50 % of cases). Experience with the reliability of dissection of big toes has led us to prefer partial toe transfer especially the wrap-around technique of Morrison. The failure rate for microsurgical transfer is 3.6 % (4).

Expect classical way of replantation also modified technique has an important role. With this technique it is possible to avoid extensive mobilization of the digital arteries as well as incisions, particularly at the distal thumb phalanx, and therefore reduce further damage of the amputated part. Prior to the osteosynthesis a venous graft is harvested from the distal forearm or from the thenar area. Anastomosis between the venous graft and radial digital artery on the amputated part of the thumb is completed. Osteosynthesis of the bones with Kirchner wires follows. The venous graft is further anastomosed to the dorsal venous system of the stump. The arterial system is reconstructed with an anastomosis of the ulnar digital artery with a superficially positioned volar vein of the amputated part. The replantation technique described has proved effective in all cases when it was used (5).

Because of favourable survival rates in replantation surgery and a high standard of free tissue transfer the interval between injury and microsurgical reconstruction has become gradually shorter. The acute phase can be defined as the interval ranging



Figs. 7, 8. Final outcome after one year – hand comparison.

from emergency procedures within 24 hours to urgent procedures done within 72 hours. Bearing in mind the infection rates that have been reported of 1.5 % for the acute phase and 17.5 % for the late phase, we should encourage emergency reconstructions. However, in most cases of upper extremity injuries, reconstruction with conventional flaps is possible. There are no significant differences in the incidence of infections when acute were compared with urgent procedures. As a result it is recommended to support the concept of urgent operations. The following advantages are to be considered: urgent operations allow a second look operation, the viability of the extremity can be assessed, and the reconstructive procedure can be planned more precisely. Last but not least, the procedure is done during the day time with better operating conditions (6).

The treatment of large and complex hand injuries is particularly challenging concerning the functional and cosmetic outcome. In this kind of injuries the primary defect cover is of paramount importance and so the initial situation for secondary reconstructive options may be evidently improved. Within the group of primary reconstruction the best results could be achieved, since radical debridement and primary defect cover by healthy tissue (free flap) led to physiological wound healing. That caused reduced hospital stay thus decreased costs, since flap failure, infection and multiple secondary surgical interventions could be diminished. Also earlier rehabilitation and reintegration into social life and profession was achievable. Due to the obtained results a primary treatment of large and complex hand injuries through radical debridement and reconstruction with free flaps seems to be effective and should already be considered in the emergency room (7). Failure rate of free flaps in a case when anastomosis is in the close vicinity of infected wound is much more higher, that is why it is advisable to made an vessel anastomosis as far as possible from recipient area.

There are a lot of possibilities how to make a finger reconstruction after failed replantation. These include pollicization of a partially amputated digit with transposition, replantation of a less important amputated digit to the thumb stump (8). Second-

arily there is also much reconstructive procedures including metacarpal lengthening, staged reconstructions of bone and soft tissues defects and finally toe to hand transfer or its modification. Type of reconstruction is directly dependent of the level of amputation, usually more proximal levels give worse result and pose difficult therapeutic problem.

“Reposition flap” is a procedure by which it is possible to reconstruct distal phalangs distal to DIP in fingers and IP joint in the thumb. After excision of pulp remaining bone and nail bed is reattached to proximal stump with Kirschner wire and soft tissues are consequently reconstructed with a local advancement and sensitive flap (9).

Single stage thumb reconstruction is also possible with a new composite skin bone flap from the forearm. The primary vascularisation of skin and bone avoids the disadvantages of the conventional multi-staged procedures such as neurovascular insufficiency, infection and bone absorption. It does not require a surgical team with microsurgical expertise. The best indication is the reconstruction in the subtotal thumb amputation (10).

Infection after replantation is really serious complication which can endanger overall result.

An effective regimen to treat patients suffering from acute hand infection requires surgical removal of devitalized tissues, systemic administration of broad antimicrobials and ameliorating underlying systemic disease processes. The task of managing wounds consequential to surgical debridement, on the other hand, can be difficult. A vacuum-assisted wound (VAC) closing seems to be effective in managing non-healing limb wounds consequential to surgical treatment for patients suffering hand infection. Although the cost of the VAC device is high, morbidity is much lower when compared to the conventional wet-to-dry dressing technique (11).

Vacuum therapy represents a useful procedure for temporary wound coverage. Especially at hand defects, when nerves, tendons or bones following trauma or staged procedures are exposed, vacuum therapy can be successfully applied utilizing the special surgical “hand glove” technique (12).

Degloving injuries of the hand also pose a difficult reconstructive and rehabilitation challenge. After an excellent experience with split-thickness skin grafting with the vacuum-assisted closure device, there are also studies with full-thickness skin grafts and traumatized skin. The device has been used with successful reapplication of full-thickness degloved skin (13).

Soft tissue and bone infections often require lengthy treatment. The result in most cases will be poor function. The treatment can be shortened by surgical revision and highly effective local antibiotic therapy with Gentamycin-PMMA-mini-chains (14).

Treatment of infection by VAC seems very beneficial and easy method which gives surprisingly good results.

Finally said there are still sometimes patients in whom replantation of the thumb fails despite the effort to save the thumb. There are a huge number of procedures which should be used for thumb reconstructions, but there are situations when nontraditional reconstruction must be attempted.

References

1. **Lee WP, Salyapongse AN.** Thumb reconstruction. 1865 In: Green DP, Hotchkiss RN, Pederson WC and Wolfe SW. *Greens Operative Hand Surgery*. Elsevier Churchill Livingstone, 2005.
2. **Sharma S, Lin S, Panozzo A, Tepper R, Friedman D.** Thumb replantation: a retrospective review of 103 cases. *Ann Plast Surg* 2005; 55 (4): 352–356.
3. **Unglaub F, Demir E, Von Reim R, Van Schoonhoven J, Hahn P.** Long-term functional and subjective results of thumb replantation. *Microsurgery* 2006; 26 (8): 552–556.
4. **Merle M.** Reconstruction of amputated thumb: 20 years of development of techniques and indications. *Bull Acad Natl Med* 1996; 180 (1): 195–210.
5. **Sukop A, Tvrdek M, Kufa R.** The primary use of venous grafts in thumb replantation. *Acta Chir Plast* 2005; 47 (4): 103–106.
6. **Brenner P, Lassner F, Becker M, Berger A.** Timing of free microsurgical tissue transfer for the acute phase of hand injuries. *Scand J Plast Reconstr Surg Hand Surg* 1997; 31 (2): 165–170.
7. **Schwabegger AH, Anderl H, Hussl H, Ninkovic MM.** Complex hand injuries. Importance of primary repair with free flaps. *Unfallchirurg* 1999; 102 (4): 292–297.
8. **Matey P, Peart FC.** Alternatives to thumb replantation in three cases of traumatic amputation of the thumb. *Microsurgery* 1999; 19 (3): 153–156.
9. **Pelissier P, Elbaz M, Casoli V, Martin D, Baudet J.** Role of emergency reconstruction of fingers by the „reposition-flap“ technique. Report of eight cases. *Ann Chir Plast Esthet* 1998; 43 (2): 182–187.
10. **Foucher G, Van Genechten F, Merle M, Michon J.** Single stage thumb reconstruction by a composite forearm island flap. *J Hand Surg Brit* 1984; 9 (3): 245–248.
11. **Huang WS, Hsieh SC, Hsieh CS, Schoung JY, Huang T.** Use of vacuum-assisted wound closure to manage limb wounds in patients suffering from acute necrotizing fasciitis. *Asian J Surg* 2006; 29 (3): 135–139.
12. **Seyhan H, Kopp J, Polykandriotis E, Horch RE.** Vacuum-assisted closure as temporary coverage in the „problem zone hand“. *Zbl Chir* 2006; 131 (Suppl 1): 33–35.
13. **Ferbert T, Kuhfuss I, Ziegler UE.** Treatment of soft tissue defects on hand and forearm with vacuum assisted closure. *Zbl Chir* 2004; 129 (Suppl 1): 57–58.
14. **Asche G.** Experiences with gentamicin-PMMA mini-chains in hand infections. *Handchirurgie* 1980; 12 (3–4): 257–260.

Received July 25, 2008.

Accepted November 21, 2008.