

## CASE REPORT AND REVIEW

# Hemosuccus pancreaticus

Koren M<sup>1</sup>, Kinova S<sup>1</sup>, Bedeova J<sup>2</sup>, Javorka V<sup>2</sup>, Kovacova E<sup>1</sup>, Kekenak L<sup>1</sup>

1st Department of Internal Medicine, Faculty of Medicine, University Comenius, Bratislava, Slovakia.  
miso.koren@seznam.cz

**Abstract:** In this study, authors describe a rare case of a 40-year old patient with a history of chronic pancreatitis due to ethanol abuse, repeatedly hospitalized for intermittent bleeding into gastrointestinal tract (GIT). The sources of bleeding were pseudoaneurysms of the peripancreatic arteries (gastroduodenal artery, right hepatic artery) bleeding into GIT via pancreatic duct. This type of bleeding is referred as hemosuccus pancreaticus and belongs to a rare form of bleeding into upper GIT. Development of each pseudoaneurysm was monitored with a 6 month time interval. The diagnosis was established using endoscope, Doppler ultrasound and CT angiography. During the therapeutic process, while stopping bleeding, two different radiological interventions were used. In pseudoaneurysm of gastroduodenal artery, hemostasis was achieved using selective transcatheter arterial embolization (TAE) with steel coils. In the second intervention, a stent was inserted into vascular lesion.

In the discussion, authors review the problems of hemosuccus pancreaticus, epidemiology, symptoms, diagnostic and possible therapeutic approaches (Fig. 3, Ref. 31). Full Text (Free, PDF) [www.bmj.sk](http://www.bmj.sk).

Key words: Hemosuccus pancreaticus, gastrointestinal bleeding, epigastric pain.

Hemosuccus pancreaticus (synonym hemoductal pancreatitis, pseudohematobilia, Wirsungorrhagia) is a rare, but potentially life threatening bleeding into upper gastrointestinal tract via ductus pancreaticus major or ductus pancreaticus minor (Santorinorrhagia). The intensity of bleeding ranges from intermittent occult bleeding up to massive acute bleeding causing death (1). Due to a rare incidence and insufficient knowledge limited to several tens of case reports, this condition may be easily misdiagnosed.

## Case report

The patient was a 41-year old male with a 10 years history of chronic pancreatitis due to ethanol abuse, insulin dependent secondary diabetes mellitus and past cholecystectomy and cholecystojejunostomia due to obstructive ileus during cholelithiasis. The patient was examined in one clinic, as recommended by a gastroenterologist, due to severe anemia (Hgb 77 g/l) two weeks prior to hospitalization at our department. The source of bleeding was not found during this hospitalization; anemia was corrected by erythrocyte transfusion with subsequent administration of peroral iron-containing products. Patient was discharged from the hospital at his own request with hemoglobin value 90 g/l.

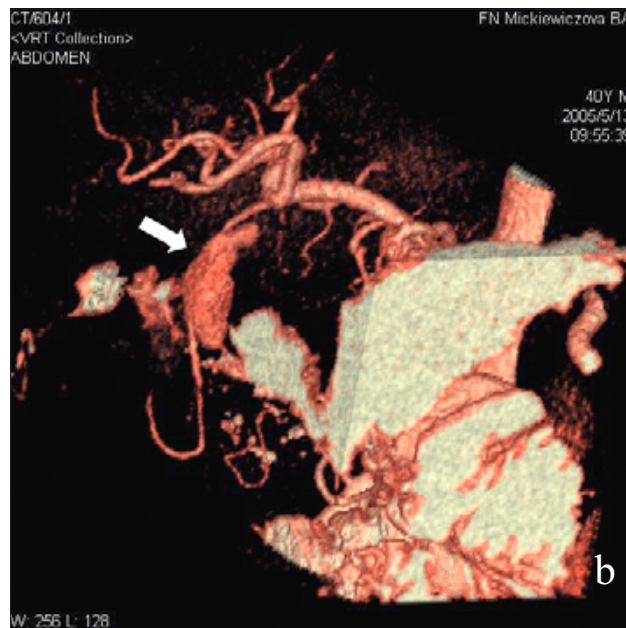
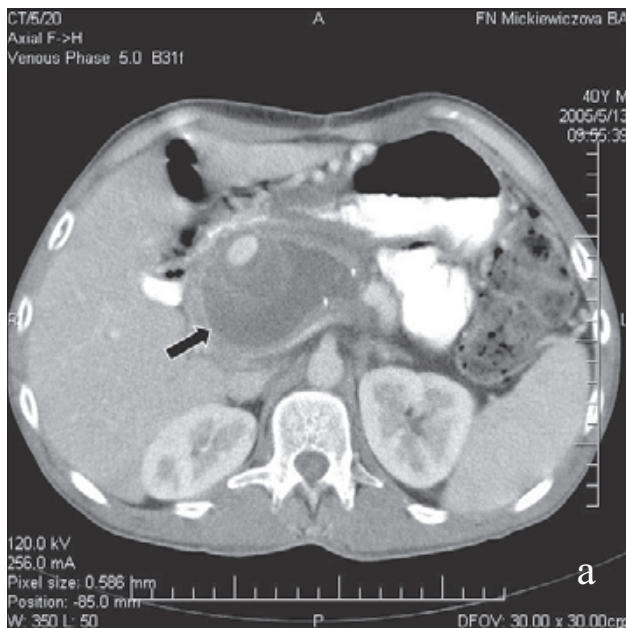<sup>1</sup>1st Department of Internal Medicine, Faculty of Medicine, University Comenius, Bratislava, and <sup>2</sup>Department of Radiology, Faculty of Medicine, University Comenius, Bratislava

**Address for correspondence:** M. Koren, MD, 1st Dept of Internal Medicine, Faculty of Medicine, University Comenius, Mickiewiczova 13, SK-813 69 Bratislava 1, Slovakia.

Phone:

It was noted in the documentation that abdominal ultrasound has revealed one lesion, 6x6 cm in size, in the caput of pancreas with both solid and cystic component.

The patient was referred to our department by a general practitioner due to severe fatigue, loss of appetite, headache, both exercise and rest induced pain of lower extremities, intermittent epigastric pain and diarrhoea (3–4 times daily). The patient reported melena last 3 days before admission. He reported a 5 years abstinence of ethanol and admitted smoking 20 cigarettes daily. The therapy of chronic pancreatitis and its complication consisted of substitution of pancreatic enzymes and short term acting insulin before main meal. During physical examination at the admission, malnutrition (BMI 17.6 kg/m<sup>2</sup>) dominated, severe paleness of skin and mucosa, tachycardia, borderline low blood pressure values (95/50 mmHg), hepatomegaly and palpable sensitive resistance 8 cm in diameter in epi- and mesogastrium was present. The blood count showed microcytary severe anemia (Ery 1.68 T/l, Hgb 4.1 g/l, MCV 80.4 fl) and slightly increased reticulocytes (1.7 %). Laboratory tests demonstrated increased sedimentation rate (FW 80/96 mm/h), positive C reactive protein (CRP 115 mg/l), increased plasma fibrinogen (Fbg 4.54 g/l), and signs of intravascular coagulation activation (D-dimer positive), hypoproteinemia and hypoalbuminemia (TP 57.4 g/l, Alb 33.6 g/l), hypokalemia (K 3.21 mmol/l), hyponatremia (Na 134 mmol/l), sideropenia (Fe 1.56 umol/l) while normal ferritin level and bad short term diabetes compensation with variable plasma glucose levels. Main coagulation parameters (INR, prothrombin time), oncologic markers, hepatic and pancreatic enzymes were within normal range. ECG showed signs of inferolateral ischemia probably due to severe anemia. An ur-

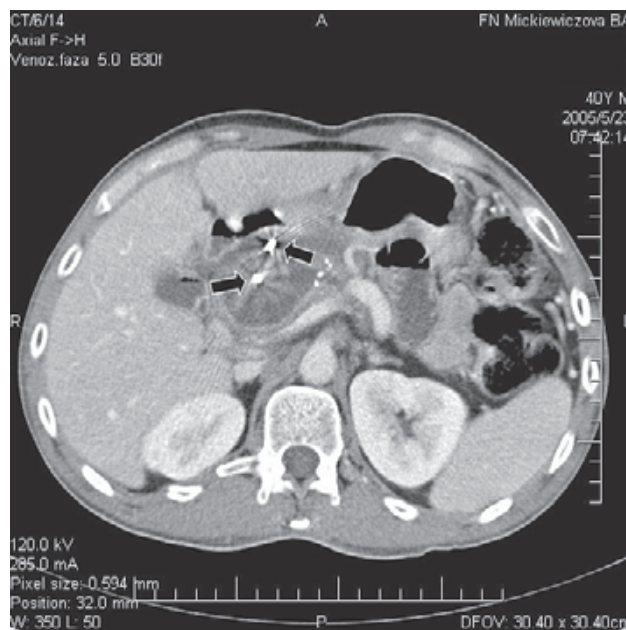


**Fig. 1. a)** The contrast-enhanced CT shows a pseudoaneurysm localized in the area of the head of pancreas. **b)** The 3D reconstruction of CT angiography revealed pseudoaneurysm of the gastroduodenal artery. Marked outpouching represents the contrast in a part of pseudoaneurysm, the rest of the vascular lesion (non seen) is filled with thrombi.

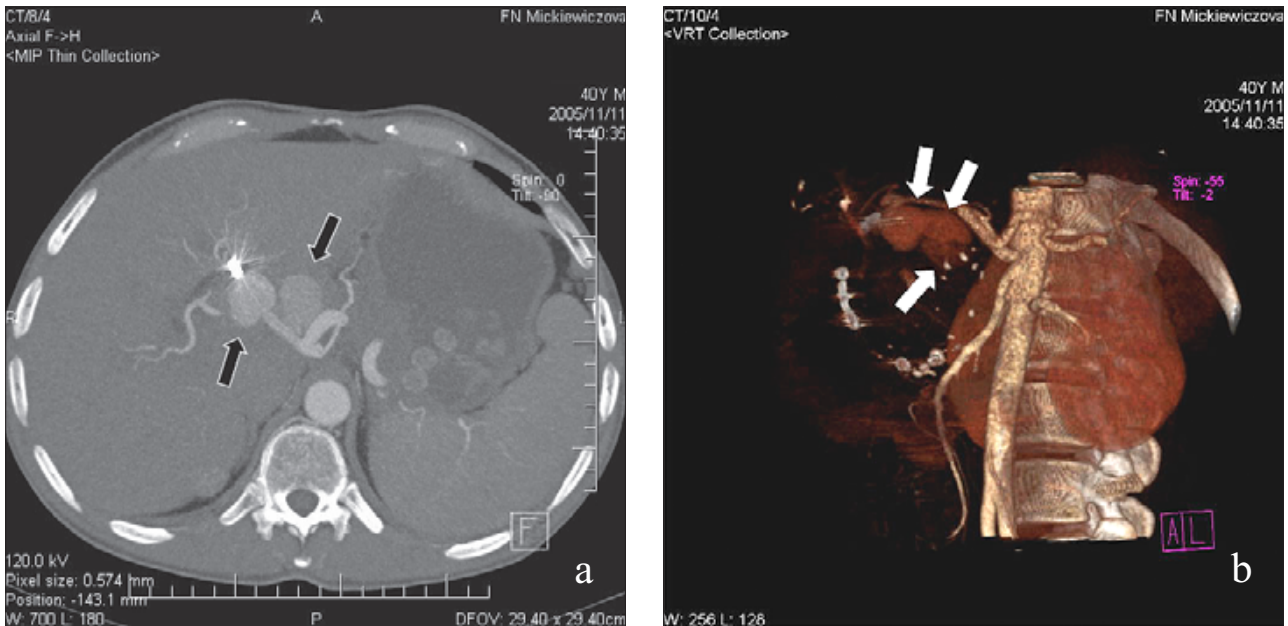
gent esophagogastrosocopy hasn't revealed neither the source of bleeding nor the presence of fresh or digested blood in examined area, but showed a deformation of duodenal bulbus due to extramural pressure. The abdominal ultrasound demonstrated a lesion (90x60mm in size) in the caput of pancreas formed by solid and fluid component, enlarged liver and dilated portal vein. At rest, with dietary measures and parenteral therapy, epigastric pain has resolved and inflammatory markers decreased spontaneously. An adjusted insulin therapy has corrected plasma glucose levels. Anemia was corrected using erythrocytes transfusion and intravenous administration of iron with subsequent increase and stabilization of hemoglobin at 100 g/l, whilst signs of anemic syndrome have resolved. While searching for the source of bleeding into GIT, colonoscopy and enteroscopy was performed with negative findings. CT of abdomen with CT angiography of truncus coeliacus revealed the cause of blood loss. In duodenal window, in the area of the head of pancreas, pseudoaneurysm of gastroduodenal artery, sized 8x6x6 cm, filled with thrombi at various stages of development and open lumen 12 mm in diameter, was found (Fig. 1). Because of its size it comprised and dilated portal vein to 22 mm. Pancreas was atrophic, caudally impressed, containing calcifications. Base on this finding, a selective transcatheter embolisation of pseudoaneurysm was indicated and performed by interventional radiologists. The material for embolization consisted of steel coils of various shape and size (3x20 mm, 5x40 mm), localized proximally and distally from the base of pseudoaneurysm and to its lumen. Control CT examination confirmed thrombotization and reduction of pseudoaneurysm (5x4x4 cm) and also a marked decrease of the pressure to portal vein (Fig. 2). Follow up and remaining course of hospitalization were without complications and patient was

discharged to ambulatory care. At the discharge, the patient has a stabilized blood pressure, without decrease in blood count and without subjective complaints.

In 6 months, the patient was again admitted to our department due to sudden severe epigastric pain and vomiting content of stomach. There weren't signs of melena, hematochesia, or



**Fig. 2.** The transcatheter arterial embolization was performed using steel coils. CT shows that the pseudoaneurysm decreased in size. Arrows mark some of the placed steel coils.



**Fig. 3. a)** CT angiography shows two from the three chamber pseudoaneurysm of the right hepatic artery (arrows). **b)** The 3D reconstructed celiac CT angiography demonstrates that the pseudoaneurysm of the right hepatic artery is built by three chambers (arrows).

hematemesis. According to the report, the patient was taking recommended drugs, limited smoking cigarettes and continued in ethanol abstinence. At admission, again palpable and sensitive resistance was present in epigastric area with pain spreading under the left costal region. Hemoglobin values were stable (Hgb 107 g/l), in contrast to previous hospitalization, a slightly increased amylase level was observed (AMS 3.23 ukat/l). An urgent CT angiography of truncus coeliacus revealed progression of pseudoaneurysm lumen in size, which was filled via new pseudoaneurysm of the right hepatic artery (Fig. 3). Repeated transcatheter embolization was not successful. After a consultation with the Clinic of vascular surgery at the National Institute of Cardiovascular Disease, the patient was transferred and a stent was inserted into the area of vascular lesion of right hepatic artery which stopped bleeding and progression of pseudoaneurysm in size. Subsequently, the patient was stabilized and discharged from the hospital without subjective complaints. Up till now, the bleeding hasn't recurred.

## Discussion

In 1931, Lower and Farrel described a bleeding via pancreatic duct due to the rupture of the spleen artery (2). The term hemosuccus pancreaticus (HP) was first used by Sandblom in 1970. In his case reports, he described three cases of bleeding via pancreatic duct; in two cases the source of bleeding was the rupture of the aneurysm of common hepatic artery and in one case aneurysm of spleen artery (3).

The most common causes of hemosuccus pancreaticus are following: 1) rupture of the pseudoaneurysm/aneurysm of peripancreatic artery into pancreatic duct and 2) bleeding of the pri-

mary intact or aneurysm containing artery to the pancreatic pseudocyst communicating with the duct. (4, 5, 6) These kinds of complication may be found mostly in chronic pancreatitis, in 2–10 %. It may be assumed that the most risky group would be men (7:1) aged 50–60 years with the history of ethanol induced chronic pancreatitis (7). The cause of development and subsequent rupture of pseudoaneurysm/aneurysm or rupture of primary intact peripancreatic artery to the pseudocyst is continuous thinning and autodigestion of vessel wall by pancreatic enzymes (elastase and trypsin) and cyst induced pressure necrosis (4). Mostly, spleen artery is affected (60–65 %), following with a decreasing incidence by gastroduodenal artery (20–25 %), pancreaticoduodenal (10–15 %), hepatic (5–10 %) and left gastric artery (2–5 %). In a treated rupture of the pseudoaneurysm, mortality ranges between 12–57 %. In an untreated rupture, mortality ranges between 90–100 % (8).

Other cause of bleeding to the pancreatic duct may be trauma and rupture of true aneurysm, caused by atherosclerosis, hereditary dystrophy of elastic tissue, fibromuscular dysplasia, syphilitic affection, vasculitis or alfa-1 antitrypsin deficit (9, 10). This type of bleeding, in most cases intraperitoneal, occurs predominantly in pregnant women or older women after many labors (11). Since 1970 till 2003, only 16 cases of hemosuccus pancreaticus caused by rupture of primary aneurysm were described in the English literature (12). Other causes of HP include acute pancreatitis causing bleeding by similar pathophysiologic mechanism like chronic form, pancreatic tumors (cystadenocarcinoma, osteoclastoma), pancreaticolithiasis, bleeding from arteriovenous malformations and pancreas divisum (13). The group of procedure-induced bleeding such as complications after endoscopic stone removal from pancreatic duct, papilosphincterectomy, en-

doscopic drainage of pseudocyst or stent insertion into duct cannot be excluded (1).

Typical clinical manifestation of HP is an abdominal pain and symptoms of bleeding into gastrointestinal tract (GIT). Pain is localized in epigastrium, directed towards back. The cause is a transient increase of intraductal pressure resulted from duct obstruction by blood clot. Approximately 48 hours after initial pain, symptoms of bleeding into GIT, such as melena, hematemesis, rarely also hematochesia, occur, decreasing the pain. Characteristic feature is **intermittent** bleeding as well as abdominal pain. Another clinical signs may be: nausea, vomiting, icterus (bile duct obstruction by blood clot in pancreaticobiliary blood reflux), anorexia, weight loss, palpable and pulsating epigastric mass and epigastric rumor (7).

Due to the intermittent character of bleeding, establishment of an accurate diagnosis is sometimes very difficult and patients are within months repeatedly hospitalized with the aim to diagnose the blood loss and abdominal pain. HP diagnosis should be suspected in every patient with the history of chronic pancreatitis and hidden bleeding into digestive tract.

In laboratory tests, depending on bleeding intensity, sideropenia and microcytary anemia or normocyte normochromic anemia of various degree, is found. In obstruction of bile duct, increased bilirubin level and normal hepatic enzymes levels are found. Pancreatic enzymes are usually within normal range with an exceptional elevation during an acute bleeding attack. Gastroscopy with direct optic usually doesn't reveal the cause of bleeding due to insufficient visualization of the Vater papilla. A duodenoscopy using a side optic has more chances. Due to the intermittent character of bleeding, even this diagnostic method reveals ongoing bleeding from papilla only in 30 % of cases. Therefore, endoscopy should be repeated when a suspicion of the bleeding into GIT persists. The indirect endoscopic signs of hemosuccus pancreaticus are blood clots in duodenum (7). Despite a low sensitivity of endoscopy in showing bleeding in hemosuccus pancreaticus, this procedure is necessary for excluding other, more frequent causes of bleeding into upper gastrointestinal tract.

The first step to determine a source of bleeding, e.g. visualization of pseudoaneurysm/ aneurysm, is a Doppler ultrasound, computer tomography (CT) using contrast agent, CT angiography and magnetic resonance of the abdomen, depending on availability (14, 15).

An endoscopic retrograde cholangio-pancreaticography with visualization of contrast agent defects, caused by blood clot in the pancreatic ducts, showing communicating pseudocyst or signs of chronic pancreatitis, may contribute to the accurate diagnosis (16). But the biggest benefit for establishing a correct diagnosis is brought by a selective angiography of celiac artery and upper mesenteric artery and their branch with 96 % sensitivity. It provides information about vascular defect as well as possible collaterals (5, 7). Although an angiography is the most sensitive method for showing pseudoaneurysm, direct communication with pancreatic duct is shown rarely (17). A radionuclid examination using <sup>99m</sup>Tc marked erythrocytes has a limited value due to intermittent character of bleeding (18).

If the diagnosis of bleeding from peripancreatic artery is established, therapeutic intervention has to be done very soon due to mortality reaching 100 % in rupture and more serious bleeding. Due to the diagnostic potential in determining the site of bleeding as well as due to therapeutic potential in stopping bleeding, first line therapy are radiological interventions (12). They provide not only short term control of bleeding in acute stages but also long term or definitive control of bleeding. The method of choice is a selective transcatheter embolization of bleeding artery or pseudoaneurysm, respectively. Medium for embolization may be temporary obstructive materials such as detachable balloons and resorptive foam materials or materials causing permanent obstruction such as steel spirals (damage of the vessel wall leads to thrombosis) and cyanoacrylate adhesives (5, 16, 19). Direct filling of the endo-aneurysmatic sack by steel spirals is not recommended due to possible expansion of lesion and risk of rupture. Obstructive material should be inserted proximally and distally from vascular defect. Described rate of success varies around 80% and mortality from 12 to 33 % (17, 20). The main complication of this intervention is embolism of "undesired" artery, post-ischemic necrosis of corresponding area when collaterals are insufficient and abscess (5, 21). Due to multiple collaterals nourishing the liver, the risk of this complication is acceptable, much worse is an accidental embolism of the lien and vessels nourishing bowels (22, 23, 24).

An alternative intervention to transcatheter embolisation is an insertion of stent into the vessel lesion. In contrast, stent doesn't cause obstruction of affected vessel and subsequent post-stenotic ischemia of corresponding tissue. According to Japanese authors, this method should be used more frequently than transcatheter embolisation in future (14, 20, 25, 26, 27). In this case report, both radiological intervention were used with good effect and without complications.

On contrary, many authors state that surgical intervention with a definitive removal of source of bleeding and therefore prevention of bleeding recurrence remains the first choice therapy (17, 28). Traditional surgical approach include bipolar arterial ligation, direct intra-pseudocystic ligation with inner or outer drainage of pseudocyst, and a resection of a part of pancreas, where pseudocyst or pseudoaneurysm is localized. Duodeno-pancreatectomy (mortality 16 %) is reserved for affection localized in the caput of pancreas and distal pancreatectomy with splenectomy (mortality 43 %) in bleeding lesions in caudal pancreas (4, 5, 13, 29). The mortality of surgical intervention ranges between 16–50 %, depending on anatomical characteristics and cause of bleeding (5). Despite a high mortality, surgical approach is an alternative when angiography fails to localize the source of bleeding, when radiological intervention fails, in hemodynamically unstable and hard to control bleeding and in cases of anatomical characteristics disabling non-surgical intervention (5, 10, 13, 30). Due to a diagnosis of chronic calcifying pancreatitis, therapeutic management of our patient will most probably be surgical intervention if bleeding recur. Because of the lack of data and studies, the recommended, evidence based optimal therapy doesn't exist (28).

In future, new solutions for maintaining hemostasis in hemosuccus pancreaticus will be found. For example, a unique intervention of Japanese surgeons in 2004, who achieved hemostasis by peri-operative transcatheter insertion of absorbable spongiiform substance into the pseudocyst after the puncture (31).

## References

1. Bureš J. Hemosuccus pancreaticus. How difficult is the diagnosis and how dangerous is the status? (Editorial). *Folia Gastroenterol Hepatol* 2005; 3: 114—116.
2. Lower WE, Farrel JI. Aneurysm of the splenic artery: report of a case and review of the literature. *Arch Surg* 1931; 23: 182—190.
3. Sandblom P. Gastrointestinal hemorrhage through the pancreatic duct. *Ann Surg* 1970; 171: 61—66.
4. Suguki T, Hatori T, Imaizumi T et al. Two cases of hemosuccus pancreaticus in which hemostasis was achieved by transcatheter arterial embolization. *J Hepatobiliary Pancreat Surg* 2003; 10: 450—454.
5. Mandel SR, Jaques PF, Mauro MA, Sanofsky S. Nonoperative Management of peripancreatic arterial aneurysms. *Ann Surg* 1987; 205 (2): 126—128.
6. Pronk NB, Haanstra WP, van der Kleij FGH. Hemosuccus pancreaticus, a rare cause of upper intestinal bleeding. *Netherlands J Med* 2003; 61 (8): 266—268.
7. Etienne S, Pessaux P, Tuech JJ, Lada P, Lermite E, Brehant O, Arnaud JP. *Gastroenterol Clin Biol* 2005; 29: 237—242.
8. Kapoor S, Pankhaj R, Pal S, Chattopadhyay TK. Hemosuccus pancreaticus: An uncommon case of gastrointestinal hemorrhage. A case report, *JOP. J Pancreas (Online)* 2004; 5 (5): 373—376.
9. Quandalle P, Gambiez L, Brami F, Ghisbain H, Andre JM, Zahredine A et al. Hémorragie digestive par rupture d'un anévrisme des artères viscérales, Présentation de quatre observations. *Chirurgie* 1998; 123: 139—147.
10. Muscari F, Barret A, Chauffour X, Bossay JP, Bloom E, Pradere B et al. Etude rétrospective de 23 cas. *Ann Chir* 2002; 127: 281—288.
11. Elton E, Howel DA, Amberson SM, Dykes TA. Combined angiographic and endoscopic management of bleeding pancreatic pseudoaneurysms. *Gastrointest Endosc* 1997; 46: 544—549.
12. Broering DC, Izbicki JR, Bloechle C, Maas R, Eisenberg CF, Broelsch CE. Hemosuccus pancreaticus als seltene Erstmanifestation einer chronischen Pankreatitis. *Chirurg* 1998; 69: 877—879.
13. Kaman L, Sanyal S, Somasekhar R. Menakuru, Singh Rajinder. Pseudoraneurysm of the superior pancreaticoduodenal artery, a rare cause of hemosuccus pancreaticus: report of a case. *Surg Today* 2004; 34: 181—184.
14. Koizumi J, Inoue S, Yonekawa H, Kunieda T. Hemosuccus pancreaticus: diagnosis with CT and MRI and treatment with transcatheter embolization. *Abdom Imaging* 2002; 27: 77—81.
15. Maltzfeld EJ, Wegener OH. Aneurysm of peripancreatic arteries in spiral CT angiography in hemosuccus pancreaticus. *Rofu Fortschr Geb Rongenstr Neuen Bildgeb Verfahr* 1997; 167: 319—321.
16. Sakorafas GH, Sarr MG, Farley DR, Que FG, Andrews JC, Farnell MB. Hemosuccus pancreaticus complicating chronic pancreatitis: an obscure cause of upper gastrointestinal bleeding. *Langenbeck's Arch Surg* 2000; 385: 124—128.
17. Dasgupta R, Davies NJ, Williamson RCN, Jackson JE. Hemosuccus pancreaticus: treatment by arterial embolization. *Clinical Radiology* 2002; 57: 1021—1027.
18. Alavi A, Ring EJ. Localization of gastrointestinal bleeding: superiority of <sup>99m</sup>Tc sulfur colloid compared with angiography. *Amer J Radiol* 1981; 137: 447—450.
19. Stösslein F, Zimmermann L, Bulang T. Embolization treatment of bleeding complications in pancreatitis. *J Hepatobiliary Pancreat Surg* 1998; 5: 344—347.
20. Ogino H, Banno T, Sato Y, Hara M, Shibamoto Y. Superior mesenteric artery stent—graft placement in a patient with pseudoaneurysm developing from a pancreatic pseudocyst. *Cardiovasc Intervent Radiol* 2004; 27: 68—70.
21. Takahashi T, Shimada K, Kobayashi N, Kakita A. Migration of steel-wire coils into the stomach after transcatheter arterial embolization for a bleeding splenic artery pseudoaneurysm: report of a case. *Surg Today* 2001; 31: 458—462.
22. Charnsangavej C, Chuang VP, Wallace S et al. Angiographic classification of hepatic arterial collaterals. *Radiology* 1982; 144: 485—494.
23. Akpınar H, Dicle o, Ellidokuz E, Okan A, Goktay Y, Tankurt E et al. Hemosuccus pancreaticus treated by transvascular selective arterial embolization. *Endoscopy* 1999; 31: 213—214.
24. Shibata T, Sagoh T, Ametani F, Maetani Y, Itoh K, Konishi J. Transcatheter microcoil embolotherapy for ruptured pseudoaneurysm following pancreatic and biliary surgery. *Cardiovasc Intervent Radiol* 2002; 25: 180—185.
25. Kuzuya A, Mizumo K, Miyake H, Iyomasa S et al. Hemosuccus pancreaticus caused by rupture of a true splenic artery aneurysm following a failure of coil embolization. *Ann Vasc Surgery* 2006; 20: 130—133.
26. Benz CA, Jakob P, Jakobs R, Riemann JF. Hemosuccus pancreaticus: a rare cause of gastrointestinal bleeding, diagnosis and interventional radiological therapy. *Endoscopy* 2000; 32: 428—431.
27. Pronk NB, Haanstra WP, van der Kleij FGH. Hemosuccus pancreaticus, a rare cause of upper intestinal bleeding. *The Netherlands J Med* 2003; 61 (8): 266—268.
28. Jun-Te Hsu, Chun-Nan Yeh, Chien-Fu Hung, Han-Ming Chen, Tsann-Long Hwang, Yi-Yin Jan, Miin-Fu Chen. Management and outcome of bleeding pseudoaneurysm associated with chronic pancreatitis.
29. Bender JS, Bouwman DL, Levison MA, Weaver DW. Pseudocysts and pseudoaneurysms: Surgical strategy. *Pancreas* 1995; 10: 143—147.
30. Boudghene F, L'Hermine C, Bigot JM. Arterial complications of pancreatitis: diagnostic and therapeutic aspects in 104 cases. *J Vasc Interv Radiol* 1993; 4: 551—558.
31. Watanabe M, Nakazaki H, Tokura N, Takita W, Kobayashi K. Intraoperative packing of pancreatic pseudocyst complicated with bleeding pseudoaneurysm. *J Hepatobiliary Pancreat Surg* 2004; 11: 422—425.

Received August 18, 2007.

Accepted December 3, 2007.