TREATMENT

Is local excision due to rectal carcinoma a safe operation?

Mracna P, Repan M, Kralik R, Skultety J

Department of Oncological Surgery, Faculty of Medicine and University Hospital, Comenius University, Bratislava, Slovakia. **bllfmed.uniba.sk@**

Abstract

Though the treatment of patients with polypoid lesions of rectum is most frequently based on endoscopic approach, there are many cases that cannot be solved endoscopically and therefore must be treated by surgeons. In the past there were several possibilities of how to operate. In reachable localisations even local operation could be performed, however with varying measures of local recurrences and survival. The aim of this article is to draw attention to the complex topic of local excisions for rectal neoplasms and at the same time to analyse the review of indication criteria and evaluate the drawbacks of this operative method in our conditions *(Tab. 3, Fig. 1, Ref. 14)*. Full Text (Free, PDF) *www.bmj.sk*.
Key words: rectal cancer local excisions, indication, criteria, pre-operative diagnosis, local recurrences.

A great part of current patients with carcinomas of low rectum can be treated radically by using a sphincter-preserving intervention. This can be done owing to many technical and oncological achievements and devices as e.g. the use of mechanical sewing apparatuses, the concept of total excision of the mesorectum in surgical treatment (14) as well as the knowledge that the distal margin of 1 cm is sufficient in well or moderately differentiated tumours. Unfortunately though, these radical interventions are associated with morbidity up to 20% and mortality in the range of 1–4 %.

In addition to the above it is necessary to count with disturbed continence, especially in the proximity of anastomosis to the dentate line or almost always in cases solved by coloanal anastomoses. Further functional disorders include fractional discharge, urge to defecate, and feelings of incomplete defecation (11).

In the past, surgical local excisions of rectal carcinoma performed by various techniques were widely performed at various clinics all over the world. It used to be indicated in cases of lesions at various stages (1, 4, 5), naturally with varying results as to the measures of local recurrences and survival (3).

They were used in an effort to avoid abdominoperineal amputation in cases of low carcinoma, in order to prevent functional disorders, and to use the advantage of their good impact on low morbidity (9, 10). The main disadvantage resided in the impossibility of pathologic staging of regional lymphatic nodes. The patients subjected to these techniques can be divided into four groups. The first group includes patients meeting the criteria of curative procedures. The second group includes cases of excessive generalisation of the disease, where the procedure does not have an impact on the prognosis, and the treatment is therefore of palliative character, namely in order to achieve local control over the disease. The third group is represented by patients with extensive co-morbidity, unable to withstand transabdominal procedures. The fourth group consists of patients who refuse to be subjected to low frontal resection of the rectum or abdominoperineal amputation according to Miles.

The objective of this paper is to focus especially on patients of the first group, in whom the use of this technique would result in local recurrence and survival measures being comparable to those subjected to radical low resection or rectum amputation by using total mesorectal excision (TME).

The allocation into the prospective studies should show whether this method is well founded, however the results found in literature are significantly inconsistent. Most of them indicate that the safety of local excisions is high, even in T3 carcinomas (8) when adjuvant chemoradiotherapy (5, 8, 9) is used. As opposed to the latter some of them warn that the use of this technique already in so-called high-risk T1 carcinomas results in high measure of local recurrences (7, 12). As the time passed, indica-

Department of Oncological Surgery, Faculty of Medicine and University Hospital, Comenius University, Bratislava, and National Institute of Oncology St. Elisabeth, Bratislava, Slovakia

Address for correspondence: P. Mracna, MD, Dept of Oncological Surgery, LFUK, Heydukova 10, SK-812 50 Bratislava 1, Slovakia. Phone: +421.2.59249111

Tab. 1. Selection of transanal excisions according to Wexner and Rotholtz et al, 13th International Symposium, Fort Lauderdale, Florida 2002.

Criteria	Indication	Contraindication
Fixation	Mobile	Semi-fixed, fixed
Accessibility	Yes (0-8cm)	No (8-15cm)
Lymphatic nodes	N0	N1
Histology (differentiation)	Good or moderate	Moderate or low
Mucous component	Absent	Present
Lymphatic/vascular invasion	Absent	Present
Size	Up to 3–4cm	Over 3–4cm
Circumference	Up to 1/3	Up to 1/3
ERUS	uT1	uT2,uT3

Tab. 2. Wexner and Rotholtz et al, 13th International Symposium, Fort Lauderdale, Florida 2002.

pT1	3–17 %
PT2	12–38 %
PT3	36–61 %

Tab. 3. Criteria of local excision: Der Chirurg 2005.

The tumour stage T1 - best infiltration of sm1, sm2.
Low-risk carcinoma G1-2, absence of lymphatic or vascular invasion
Diameter of 3 cm
Good accessibility and the condition of safe procedure preferably by use of TEM

tion criteria were changing as well as the technique of procedure and used instruments. In the past ten years, the classical transabdominal „radical“ procedures have been subjected to significant changes. The techniques as Kraske's parasacral resection and resection according to Mason are being performed rarely due to their high measure of morbidity especially when associated with infectious complications (10, 12). Out of them, the classical transanal local excision is still being used with instruments of transanal endoscopic microsurgery (2, 6). The possibility of 6-fold magnification enabled by the latter technique has brought about an improvement in the quality of operation by means of improving the view of the operation field, augmenting the distinction of the resection line, advancing the practical accessibility up to the peritoneal reflection, and at the same time it has decreased the per-operational risk (2, 12).

Good knowledge of biology of the rectal carcinoma in the studies of German anatomists led by German pathologists 40 years ago as well as the revolutionary contribution of Dr. Heald and his colleagues to the knowledge of the spreading of rectal tumours within the mesorectum have introduced the method of surgical therapy referred to as total excision of mesorectum (14) into practice. It represented a significant benefit as to the improved survival and significantly decreased local recurrences. At the same time the knowledge of tumour spreading, especially in the middle and low thirds of the rectum – lymphatic metastases and discontinuous spreading of rectal tumours up to the distance of 4 cm from the primary tumour, including the distal spreading from the low border of primary tumour has led to postulating the importance of radial excision margin in transabdominal resection.

The techniques based on local excision have brought about the necessity to specify the indication criteria as shown in Tables 1–3. Owing to the significant increase in the development of metastases in the regional lymph nodes, the risk of which is proportional with the depth of invasion as shown in Table 2, these criteria often become precarious and require urgent answers to a number of questions arising in the light of staging by means of endorectal ultrasonography and magnetic resonance.

The latest publications report high measure of local recurrences (3) after conventional local excisions. The reasons most probably reside in insufficient visualisation of the operation field due to the absence of microsurgery, thus increasing the probability of per-operational fragmentation of tumour and insufficient depth or width of the resection margin of excision (16).

Analysis

In our conditions a question is remaining unanswered as to whether the information gained by pre-operational staging, imaging or from pathologists is sufficient for us to be able to responsibly select patients for this operational technique. For the patient, this selection is a crucial step. Should a polypoid lesion be endoscopically removed, as soon as the pathologist finds out that carcinoma was restricted to the polyp with no signs of infiltration in its base, further radical intervention is not indicated. The situation is however different in T1 carcinomas found to be invading the submucosa. In such cases the literature presents the following percentages of probability of metastases within the regional lymphatic nodes, while a number of reports note that there is a high risk of lymphatic metastases in patients with tumours localized in the low third of the rectum. However this is the very site where local excisions are used. The German experts have managed to differentiate three layers within the submucosa by means of endorectal untrasonography by use of a 20 MHz probe. They investigated patients after local excisions with various stages of infiltration into the submucosa. The classification according to Kudo (13) is involved. They have found out that the results in sm1 and sm2 infiltrations are the same and local recurrences are nil. They indicate that the most profound sm3 is risky owing to the incomparable high risk of local recurrences (0 % vs 22 %) also in so-called low-risk T1 carcinomas. When such a depth of invasion is found after the operation they indicate an urgent re-operation either in sense of rectal amputation or low resection. Should the patient disagree, the utmost possibility is the concomitant radiochemotherapy as the prognosis of recurrences found by dispensaries is much worse as far as the rate of 5-year survival is concerned (94 % vs 55 %), despite the fact that the re-operation is possible in a large percentage of patients (10, 11, 12).

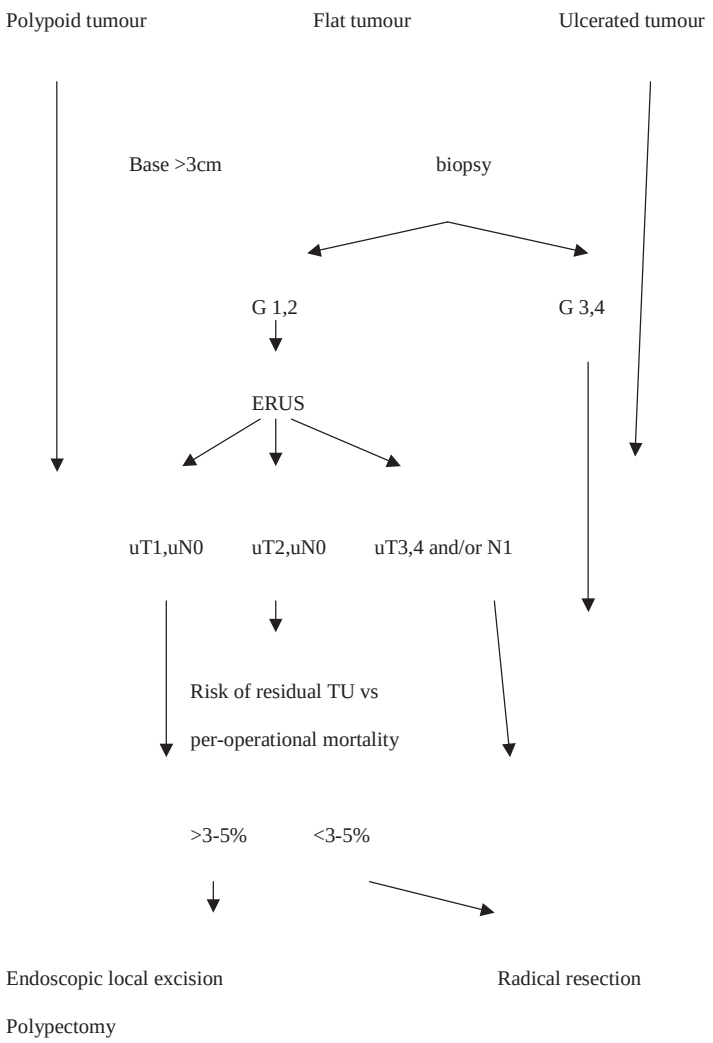

Fig. 1. The possibilities of the way out of these difficult decisions.

The pre-operational histology is not always available, i.e. should a polypoid lesion be endoscopically removed and after the operation it is found out that the carcinoma is restricted to the polyp and its base bears no signs of infiltration, further radicalisation is not indicated. This means that such a patient does not have to be treated surgically. Should the tumour not be removed endoscopically, a sample is usually taken to be histologically examined. According to statistics, only one third of samples are proved to be carcinomas at a stage or lymphovascular infiltration not specified by pathologist. No staging imaging methods, namely neither endorectal sonography nor endorectal magnetic resonance are able to assess the depth of infiltration reliably, especially in submocosa. In addition to the latter, the availability of of transanal endoscopic microsurgery is restricted to a small number of clinics due to the high price of the apparatus. The summary of the above facts implies that there are several questions remaining to be answered. Can we in our conditions afford to perform local excision in a patient who otherwise would be able to physically withstand the radical intervention of low resection or amputation of the rectum with total mesorectal excision? Is the high risk of local recurrence and distant metastases appropriate? Is the adjuvant therapy in form of concomitant chemoradiotherapy able to decrease the rate of recurrences to the level achieved by transabdominal radical resection by use of total mesorectal excision?

These questions need time to be reliably answered in order to position the diagnosis and local excisions in the pre-operative therapy of rectal carcinoma.

Summary: In our conditions we are not able to assess reliably the depth of infiltration, N stage according to CT, MRI, endorectal sonography etc. Pathologists do not report the grading and other characteristics, and transanal endoscopic microsurgery is not available. The arranged algorithm shows the possibilities of the way out of these difficult decisions (Fig. 1).

Conclusion

Under the condition of reliable pre-operational assessment of these criteria, it is possible to perform curative treatment in form of local excision in T1 sm1,2 invading carcinomas lacking the mucous component, lymphovascular invasion with G1,2, with NO status, up to the diameter of 3 cm, with the safety margin of ca 1 cm, preferably by use of instruments for transanal endoscopic microsurgery. In the rest of cases these criteria can be disregarded only when taking into account the co-morbidity of patient, or his refusal to be subjected to radical intervention.

Regarding the fact that in Slovak conditions of strict meeting the above algorithms and indications it is not possible to rely on pre-operational imaging methods and due to insufficient information from pathologists, most local excisions cannot be probably performed without inadequate risk of local recurrences or distant dissemination.

References

1. Balani A, Turoldo A, Braini A, Scaramucii M, Roseano M, Leggeri A. Local excision for rectal cancer. J Surg Oncol 2000; 74 (2): 158—162.

2. Lev-Chelouche D, Margel D, Goldman G Rabau MJ. TEM: experience with 75 rectal neoplasms. Dis Colon Rectum 2000; 43 (5): 662—667.

3. Garcia-Aquilar J, Mellgren A, Sirivongs P, Buie D, Madoff RD, Rothenberger DA. Local excision of rectal cancer without adjuvant therapy: a word of caution. Ann Surg 2000; 231 (3): 345—351.

4. Chakravarti A, Compton CC, Shellito PC, Wood WC, Landry J, Machuta SR, kaufman D, Ancukiewicz M, Willett CG. Long-term follow up of patients with rectal cancer managed by local excision with and without adjuvant irradiation. Ann Surg 1999; 230 (1): 49—54.

5. Le Voyer TE, Hoffman JP, Cooper H, Ross E, sigurdson E, Eisenberg B. Local excision and chemoradiation for low rectal T1 and T2 cancers is an effective treatment. Amer Surg 1999; 65 (7): 625—630.

6. Benoist S, Taffinder N, Gould S, Ziprin P, Chang A, Darzi A. Transanal endoskopic microsurgery: a forgotten minimally invasive technique. Gastroenterol Clin Biol 2001; 25 (4): 369—374.

7. Heintz A, Morschel M, Junginger T. Rectal carcinoma. Optimizing therapy by local excision. Zbl Chir 1999; 124 (5): 436—440.

8. Graham RA, Hackford AW, Wazer DE. Local excision of rectal carcinoma: a safe alternative for more advanced tumors? J Surg Oncol 1999; 70 (4): 235—238.

9. Chorost MI, Petrelli NJ, McKenna M, Kraybill WG, Rodriguez I. Local excision of rectal carcinoma. Amer Surg 2001; 67 (8): 774—779.

10. Matzel KE, Merkel S, Hohenberger W. Lokale therapieprinzipien beim rektumkarzinom. Der Chirurg 2003.

11. Liersch T, Langer C, Ghadimi BM, Becker H. Aktuelle behandlungsstrategien beim rektumkarzinom. Der Chirurg 2005.

12. Schäfer H, Baldus SE, Gasper F, Holscher AH. Transanale endoskopische mikrochirurgie beim pT1-low-risk-rektumkarzinom. Der Chirurg 2005; 4.

13. Kudo S, Soga J, Yamamoto M, Koyama S, Muto T. Treatment of colorectal sm-carcinomas. Stomach Intestine 1984; 19: 1349—1356.

14. Heald RJ, Husband EM, Ryall RDH. The mesorectum in rectal cancer surgery. The clue to pelvic recurrence. Brit J Surg 1982; 69: 613—616.

Received August 30, 2006.
Accepted January 26, 2997.