

CLINICAL STUDY

Changes in collagen and elastic fiber contents of the skin, rectus sheath, transversalis fascia and peritoneum in primary inguinal hernia patients

Ozdogan M, Yildiz F, Gurer A, Orhun S, Kulacoglu H, Aydin R

Department of Surgery, Ataturk Teaching and Research Hospital, Bilkent, Ankara, Turkey. hakankulacoglu@hotmail.com

Abstract

Background: It has been claimed that inguinal hernia is not a local disease; it is a local manifestation of a systemic disorder of collagen metabolism. Previous studies have shown that patients with inguinal hernia have some anomalies in collagen metabolism and changed ratio of collagen types.

Aim: To search the changes in collagen and elastic fiber contents of the skin, rectus sheath, transversalis fascia and peritoneum in primary inguinal hernia patients.

Methods and materials: Twenty patients operated on for inguinal hernia (HR) included in the study (11 direct and 9 indirect). Nine patients underwent open cholecystectomy served as the control group (CC). A 0.5 x 1 cm. tissue was sampled from skin, rectus sheath, transversalis fascia and peritoneum in HR group. Skin, rectus sheath and peritoneum samples were taken from the patients in CC group. The sections of those samples were submitted to two different staining methods: "Masson's trichrome" for collagen and "van Gieson" for elastin fibers and graded with light microscopy.

Results: The rectus sheath samples of CC had higher staining scores for both collagen and elastin fibers in comparison with HR ($p=0.032$ and $p=0.026$, respectively). CC had a significantly higher score for collagen in peritoneum samples ($p=0.019$). There were no statistically significant differences between the patients with direct and indirect inguinal hernias for collagen or elastin fibers scores in skin, rectus sheath, transversalis fascia and peritoneum samples.

Conclusions: These findings, which concur with most of the previous studies, support the theory that inguinal hernia may not be merely a local disease and can be more generalized, at least a regional connective tissue disorder. Regarding the difference between direct and indirect hernias, it could not be possible to report a certain answer, and this issue should be considered together with previous quantitative researches and more sophisticated studies may take place in the future (Tab. 2, Fig. 2, Ref. 23).
Key words: inguinal hernia, collagen, elastin.

Inguinal hernia is probably the most common surgically treatable disease (1). Open processus vaginalis, elevated intraabdominal pressure and disordered shutter mechanism may be responsible for the development of inguinal hernias (2). However, one new concern has gained great interest among the surgeons and biomedical researchers in the last years: changes in connective tissue.

In fact, possible role of connective tissue alterations in inguinal hernias was first implicated decades ago (3). More recent studies have focused on collagen which is the most abundant extracellular matrix protein. It has been shown that patients with inguinal hernia have some anomalies in collagen metabolism and changed ratio of collagen types (4–9).

When it comes to inguinal hernias, transversalis fascia is the main anatomic structure. It has two structural components: collagen and elastin. Therefore, some studies which have searched the correlation between disordered connective tissue and inguinal hernia have examined the transversalis fascia (10–12). On the other hand, some others have claimed that inguinal herniation is not a local disease. It was suggested that inguinal herniation rep-

Department of Surgery and Department of Histopathology, Ataturk Teaching and Research Hospital, Bilkent, Ankara, Turkey

Address for correspondence: H. Kulacoglu, MD, Bahcelievler, 1. cadde, 109/5, 06490 Ankara, Turkey.

Phone: +90.532.2574050, Fax: +90.312.4171440

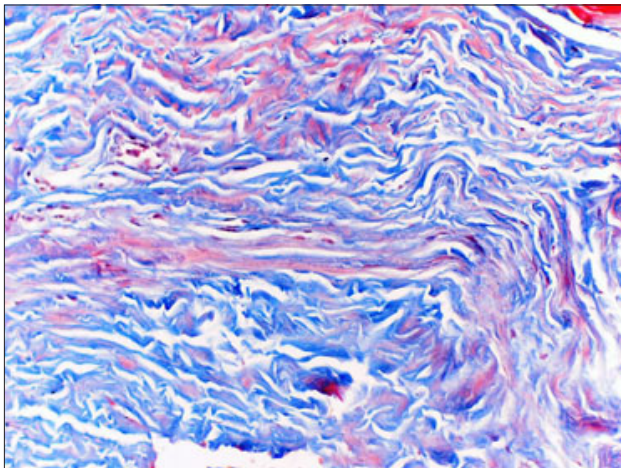


Fig. 1. Grade 3 staining for collagen in rectus sheath (Masson's trichrome, X100).

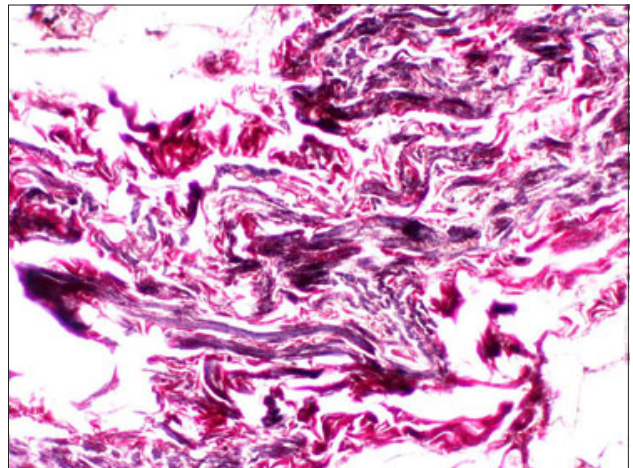


Fig. 2. Grade 3 staining of elastin fibers in rectus sheath (van Gieson, X100).

resents a local manifestation of a systemic disorder of collagen metabolism. Therefore transversalis fascia, hernia sac, rectus sheath and the skin of patients with hernia was investigated (4, 5, 7, 9, 13). However, according to our recent MEDLINE searching, no single study has examined these four layers of the abdominal wall in the same subjects.

This prospective controlled study examined the changes in collagen and elastic fiber contents of the skin, rectus sheath, transversalis fascia and peritoneum in primary inguinal hernia patients. The patients underwent cholecystectomy for cholelithiasis at the same clinic in the same period served as the control group of the study.

Methods

This study was approved by the local ethics committee of our institute. An informed consent was signed by every patient. Twenty patients with inguinal hernia operated on between December 1, 2004 and January 31, 2005 were prospectively included in the study (HR). Eleven patients had a direct hernia (DH) and other nine had indirect hernia (IH). Patients with bilateral or recurrent inguinal hernias and femoral hernia were excluded. All hernia repairs were tension-free and performed through a trans-

vers inguinal incision. Nine patients who underwent open cholecystectomy for cholelithiasis via subcostal incision were included in the study as the control group (CC). These patients had no present inguinal hernia and previous abdominal surgery.

A 0.5 x 1 cm. tissue was sampled from skin, rectus sheath, transversalis fascia and peritoneum (hernia sac) in HR group. Skin, rectus sheath and peritoneum samples were taken from the patients in CC group. The tissue samples were fixed in 10 % formaldehyde solution and sent to pathology department with no further information about the patient except for the study protocol number.

Histopathological evaluation

The samples were embedded in paraffin and 4 μ sections were submitted to two different staining methods: for "Masson's trichrome" collagen and "van Gieson" for elastin fibers. The slides were examined randomly under light microscopy. They were graded as dense (grade 3), moderate (grade 2) and poor (grade 1) according to their staining density.

Statistical analysis

This was carried out using Statistical Package for Social Science (SPSS) software. Variance analysis was done with ANOVA.

Tab. 1. Collagen and elastin fiber scores for skin, rectus sheet and peritoneum in hernia and control groups.

	Skin			Rectus Sheath			Peritoneum		
	Grade 1	Grade 2	Grade 3	Grade 1	Grade 2	Grade 3	Grade 1	Grade 2	Grade 3
CC									
Collagen	0	8 (88.9%)	1 (11.1%)	0	4 (44.4%)	5 (55.6%) ^a	0	6 (66.7%)	3 (33.3%) ^c
Elastin	0	0	9 (100.0%)	4 (44.4%)	1 (11.1%)	4 (44.4%) ^b	3 (33.3%)	2 (22.2%)	4 (44.4%)
HR									
Collagen	1 (5.0%)	19 (95.0%)	0	7 (35.0%)	10 (50.0%)	3 (15.0%) ^a	9 (45.0%)	10 (50.0%)	1 (5.0%) ^c
Elastin	0	2 (10.0%)	18 (90.0%)	3 (15.0%)	13 (65.0%)	4 (20.0%) ^b	6 (30.0%)	10 (50.0%)	4 (20.0%)

^ap=0.032, ^bp=0.026, ^cp=0.019

Tab. 2. Collagen and elastin fiber scores for skin, rectus sheath, transversalis fascia and peritoneum in direct and indirect hernia patients.

	Skin			Rectus sheath			Transversalis fascia			Peritoneum		
	Grade 1	Grade 2	Grade 3	Grade 1	Grade 2	Grade 3	Grade 1	Grade 2	Grade 3	Grade 1	Grade 2	Grade 3
DH												
Collagen	1 (11.1%)	8 (88.9%)	0	3 (33.3%)	4 (44.4%)	2 (22.2%)	4 (50.0%)	3 (37.5%)	1 (12.5%)	1 (11.1%)	8 (88.9%)	0
Elastin	0	2 (22.2%)	7 (77.8%)	2 (22.2%)	7 (77.8%)	0	1 (12.5%)	6 (75.0%)	1 (12.5%)	2 (22.2%)	6 (66.7%)	1 (11.1%)
IH												
Collagen	0	11 (100.0%)	0	4 (36.4%)	6 (54.5%)	1 (9.1%)	2 (18.2%)	6 (54.5%)	3 (27.3%)	0	11 (100.0%)	0
Elastin	0	0	11 (100.0%)	1 (9.1%)	6 (54.5%)	4 (36.4%)	2 (18.2%)	7 (63.6%)	2 (18.2%)	4 (36.4%)	4 (36.4%)	3 (27.3%)

Chi-square test was used to compare the groups. Values of $p < 0.05$ were considered to be significant.

Results

The mean age of the patients in HR and CC groups were similar (46.45 ± 20.47 vs 50.44 ± 11.96 , $p = 0.593$). The rectus sheath samples of the control group had higher staining scores for both collagen (Fig. 1) and elastin (Fig. 2) fibers in comparison with hernia group (Tab. 1). These differences were statistically significant ($p = 0.032$ and $p = 0.026$, respectively). In addition, the control group had a significantly higher score for collagen in peritoneum samples ($p = 0.019$). On the other hand, there were no statistically significant differences between the patients with direct and indirect inguinal hernias for collagen or elastin fibers scores in skin, rectus sheath, transversalis fascia and peritoneum samples (Tab. 2).

Discussion

Raymond Read, in 1967, performed a hernia repair for a direct inguinal hernia in a young man with attenuated rectus sheath and transversalis fascia and thought that "Hernia might be a connective tissue disorder" (3). Three years later, he reported that the rectus sheath samples taken from the patients with direct inguinal hernia had the most attenuation, controls least, and the indirect hernia between (14). His subsequent studies have revealed that the rectus sheath in direct inguinal hernia patients has irregularly arranged collagen fibers (15, 16).

Collagen is the end product of activity within a fibroblast. Among its different types, type I and type III are important. Type I collagen is dominant in the mature wound, whereas type III dominates during the early stages of wound healing, and is not a strong barrier to save the man from herniation (5). The ratio between collagen type I and III determines the tensile strength and mechanical stability of the connective tissue and scar tissue (17–19). Klinge et al have reported that collagen type I/III ratio in the skin samples is lower in the hernia patients than the controls (7). Friedman has also shown a statistically significant difference in collagen type I/III ratios of skin fibroblasts isolated from hernia patients and control individuals (5). However, recently, Pans et al have found no difference in type I/III ratio in transversalis fascia of hernia and control patients (8).

In a very recent microscopic study, Borquez and colleagues have found a 52 % lower collagen fiber density in the skin from the patients with inguinal hernia, compared to subjects without hernia, whereas no differences has been shown in elastic fiber density (13). In the present study, using the same staining techniques, no differences have been observed in light microscopy examination scores of the skin collagen and elastin between HR and CC groups. However, the rectus sheath has displayed poorer results in HR group for both collagen and elastin fibers. The elastin fibers are the elements responsible for the reversible distensibility of the connective tissue. It has been shown that a healthy elastin fiber structure is the key for normal tissue architecture, promotes withdrawal of the tissue to its original size and shape when submitted to a mechanical force (20). Disordered elastin fibers may be a cause of hernia development.

When a researcher would like to investigate connective tissue disorder in hernia patients, one question arises: "Are there differences between direct and indirect hernias?" In general, it has been accepted that indirect hernias in adults is congenital in origin as in infants (21). However, some authors believe that a patent processus vaginalis is not necessary for the development of all inguinal hernias in adults, using the term: "acquired indirect inguinal hernias" (22). In fact, simple herniotomy and high ligation which is the surgical treatment of infant hernias usually results in recurrence when the patient is adult. Thus, a connective tissue disorder may be responsible for indirect hernias as well.

As one of the leading research team in herniology, Aachen group have reported that both direct and inguinal hernias display altered structural integrity and mechanical stability of the connective tissue with no statistical difference (7). Similarly, Rodrigues Junior et al have found significantly lower amounts of collagen with colorimetric quantification in transversalis fascia from patients with direct hernia compared to indirect hernia patients (12). Interestingly, they have reported a higher staining density for elastin fibers in direct hernia patients. In the present study, we have observed that skin, rectus sheath and peritoneum have very similar scores for both collagen and elastin fibers in direct and indirect hernia patients. Transversalis fascia collagen staining is poorer in direct hernia in comparison with indirect hernia, but this difference has not reached statistical significance ($p = 0.325$). At this point, we think it is better to rely on the results of previous studies using quantitative biochemical methods rather than histopathological examination.

Some other authors have also reported conflicting results. Pans et al (8) have found an increased collagen concentration in the indirect hernias. Bellón and colleagues have searched matrix metalloproteinases (MMPs) which are the key enzymes participating in collagen degradation using immunochemical methods. They reported no significant difference in principal matrix enzyme MMP-1 staining of fascia transversalis from direct hernias when compared with that of the indirect hernias, while a strong reaction against MMP-2 has been observed in direct hernias in contrast to a poor reaction in indirect hernias (6). The same study has detected no differences in proline hydroxylation between each type of hernia, and a small decrease in lysine hydroxylation in patients with direct hernia. More recently, Abci et al using immunohistochemical method have found that tissue inhibitor of metalloproteinase-2 (TIMP-2) scores of direct inguinal hernias are significantly less than those of the control group (23). They have proposed that this decreased TIMP-2 scores in patients with a direct inguinal hernia, compared with both the indirect inguinal hernia group and the control group may explain the role of TIMP-2 in inguinal hernia development.

Although the present study has shortcomings in its qualitative method, a meticulous staining work and histopathological observation has revealed a clear difference in rectus sheath examination scores between inguinal hernia and control patients, with a significant difference in collagen staining between their peritoneal samples. This finding, which concurs with most of the previous studies in the same field, supports the theory that inguinal hernia may not be merely a local disease and can be more generalized, at least a regional connective tissue disorder. Regarding the difference between direct and indirect hernias, it could not be possible to report a certain answer, and this issue should be considered together with previous quantitative researches and more sophisticated studies may take place in the future.

References

- Rutkow IM.** Demographic and socioeconomic aspects of hernia repair in the United States in 2003. *Surg Clin North Amer* 2003; 83: 1045–1053.
- Abramson J.** Etiology and pathophysiology of primary and recurrent groin hernia formation. *Surg Clin North Amer* 1998; 78: 953–973.
- Read RC.** Inguinal herniation in the adult, defect or disease: a surgeon's odyssey. *Hernia* 2004; 8: 296–299.
- Ajabnoor MA, Mokhtar AM, Rafee AA, Taha AM.** Defective collagen metabolism in Saudi patients with hernia. *Ann Clin Biochem* 1992; 29: 430–436.
- Friedman DW, Boyd CD, Norton P, Greco RS, Boyarsky AH, Mackenzie JW et al.** Increases in type III collagen gene expression and protein synthesis in patients with inguinal hernias. *Ann Surg* 1993; 218: 754–760.
- Bellón JM, Buján J, Honduvilla NG, Jurado F, Gimeno MJ, Turmay J, Olmo N, Lizarbe MA.** Study of biochemical substrate and role of metalloproteinases in fascia transversalis from hernia processes. *Eur J Clin Invest* 1997; 27: 510–516.
- Klinge U, Zheng H, Si Z, Schumpelick V, Bhardwaj RS, Muys L, Klosterhalfen B.** Expression of the extracellular matrix proteins collagen I, collagen III and fibronectin and matrix metalloproteinase-1 and -13 in the skin of patients with inguinal hernia. *Europ Surg Res* 1999; 31: 480–490.
- Pans A, Albert A, Lapiere CM, Nusgens B.** Biochemical study of collagen in adult groin hernias. *J Surg Res* 2001; 95: 107–113.
- Rosch R, Klinge U, Si Z, Junge K, Klosterhalfen B, Schumpelick V.** A role for the collagen I/III and MMP-I/-13 genes in primary inguinal hernia. *BMC Med Genet* 2002; 3: 2. (www.biomedcentral.com/1471-2350/3/2)
- Rodrigues Junior AJ, Castro de Tolosa EM, Ferraz de Carvalho CA.** Electron microscopic study on the elastic and elastic related fibers in the human fascia transversalis at different ages. *Gegenbaurs Morphol Jahrb* 1990; 136: 645–652.
- Quintas ML, Rodrigues CJ, Yoo JH, Rodrigues AJ.** Age related changes in the elastic fiber system of the interfoveolar ligament. *Rev Hosp Clin Fac Med S Paulo* 2000; 55: 83–86.
- Rodrigues Junior AJ, Rodrigues CJ, Pereira da Cunha AC, Yoo J.** Quantitative analysis of collagen and elastic fibers in the transversalis fascia in direct and indirect inguinal hernia. *Rev Hosp Clin Fac Med S Paulo* 2002; 57: 265–270.
- Borquez P, Garrido L, Manterola C, Pena P, Schlageter C, Orellana JJ, Ulloa H, Pena JL.** Study of collagen and elastic fibers of connective tissue in patients with and without primary inguinal hernia. *Rev Med Chil* 2003; 131: 1273–279.
- Read RC.** Attenuation of the rectus sheath in inguinal herniation. *Amer J Surg* 1970; 120: 610–614.
- Wagh PV, Read RC.** Defective collagen synthesis in inguinal herniation. *Amer J Surg* 1972; 124: 819–822.
- Wagh PV, Leverich AP, Sun CN, White HJ, Read RC.** Direct inguinal herniation in men: a disease of collagen. *J Surg Res* 1974; 17: 425–433.
- Henkel W, Glanville RW.** Covalent crosslinking between molecules of type I and III collagen. *Europ J Biochem* 1982; 122: 205–213.
- Fleischmajer R, Perlish JS, Burgeson RE, Shaikh-Bahai F, Timpi R.** Type I and type III interactions during fibrillogenesis. *Ann NY Acad Sci* 1990; 580: 161–175.
- Friedman DW, Boyd C, Mackenzie JW, Norton P, Olson RM, Beak SM.** Regulation of collagen in keloids and hypertrophic scars. *J Surg Res* 1993; 55: 214–222.
- Imayama S, Braverman IM.** A hypothetical explanation for the aging of the skin. *Amer J Pathol* 1989; 134: 1019–1025.
- van Wessem KJP, Simons MP, Plaisier PW, Lange JF.** The etiology of indirect inguinal hernias: congenital and/or acquired? *Hernia* 2003; 7: 76–79.
- Kahn AM, Hamlin JA, Thompson JE.** The etiology of the adult indirect inguinal hernia: Revisited. *Amer Surg* 1997; 11: 967–969.
- Abci A, Bilgi S, Altan A.** Role of TIMP-2 in fascia transversalis on development of inguinal hernias. *J Invest Surg* 2005; 18: 123–128.

Received March 22, 2006.

Accepted May 15, 2006.