CASE REPORT

Acute toxicity of propafenone in a case of suicidal attempt

Stancak B, Markovic P, Rajnic A, Petrikova V

3rd Department of Internal Medicine, L. Pasteur's University Hospital, Kosice, Slovakia. **bll@fmed.uniba.sk**

Abstract

We describe a successful treatment of 28-year old man who ingested in a suicidal attempt up to 30 pills each containing 150 mg (4500 mg) of propafenone. Results of clinical toxicology were obtained with high performance liquid chromatography from the urine sample. Semiquantitative analysis has shown a high peak for propafenone hydrochloride. The main clinical findings were coma, hypotension, acidosis, sinoatrial block, junctional tachycardia and ventricular arrhythmias necessitating defibrillation. Maximum occurence of arrhythmias was observed 2.5 hours after hospital admission, while the cessation of toxic signs started 4.5 hours later. Gastric lavage, arteficial ventilation, administration of alkalinization solutions and management of rhythm disorders were the most important therapeutic measures in this case. *(Fig. 2, Ref. 18.)*
Key words: antiarrhythmic drugs, arrhythmia, overdose, toxicity, resuscitation.

Propafenone is a well-established I C class antiarrhythmic drug widely used in the treatment of a variety of supraventricular and ventricular tachyarrhythmias (1). We describe a successful treatment of a 28-year old man who ingested in a suicidal attempt up to 30 pills, each containing 150 mg (4500 mg) of propafenone.

Case summary

This man was admitted to the emergency unit of the University hospital after he was found at a city bus station in the state of severe deterioration of consciousness with signs of ethanol abuse and rapidly worsening muscular weakness unallowing him to maintain active position. Several empty blisters of propafenone, verapamil and benzodiazepine bromazepamum were found in his clothing. At the time of admission the patient was somnolent, sweating, pale, and hypotensive with blood pressure 80/20 mmHg. The manifestations involved intermittent myoclonic spasms of the face and limbs with a tendency to opisthotonus, floating divergent eye bulbs and isocoric mydriasis with delayed photoreaction. The head was mesocephalic with out signs of trauma, the tongue was not bitten. Breathing was superficial without rales. Jugular veins were not dilated. Cardiac action was regular, rate 65/min and heart sounds were silent. The abdomen was soft but peristalsis was silent. No signs of congestion were present. An initial electrocardiogram showed sinus rhythm with prolonged PR interval (250 ms) and wide QRS complexes with duration of 160 ms. Within one hour after the admission a deep coma with stem syndrome and right sided lateralization with out reaction to algic impulses developed. Because of the ventilation worsening and an increase of hypoxaemia and cyanosis the patient was intubated and an arteficial ventilation was established. The lavage of the stomach and initiation of a forced diuresis followed. In 2.5 hours after the admission several paroxysms of ventricular tachycardia and ventricular fibrillation occured. They were preceded by bizzare ventricular ectopic beats. Paroxysms were in part self-terminating but external defibrillation was neccessary 6 times. Episodes of ventricular arrhythmia were followed by marked ventricular asystole and missing atrial activity. Clinically, epileptic convulsions and severe hypotension persisted. Arrhythmic period lasted for 40 minutes, then a stable junctional rhythm with a rate of 90/min and marked abberation of

3rd Department of Internal Medicine, L. Pasteur's University Hospital, Kosice, Emergency Care Unit, L. Pasteur's University Hospital, Kosice, 4th Department of Internal Medicine, L. Pasteur's University Hospital, Kosice, Department of Clinical Pharmacotoxicology, L. Pasteur's University Hospital, Kosice, Slovakia

Address for correspondence: B. Stancak, MD, PhD, 3rd Dept of Internal Medicine, L. Pasteur's University Hospital, Rastislavova 43, SK-041 90 Kosice, Slovakia.
Phone: +421.55.7882723

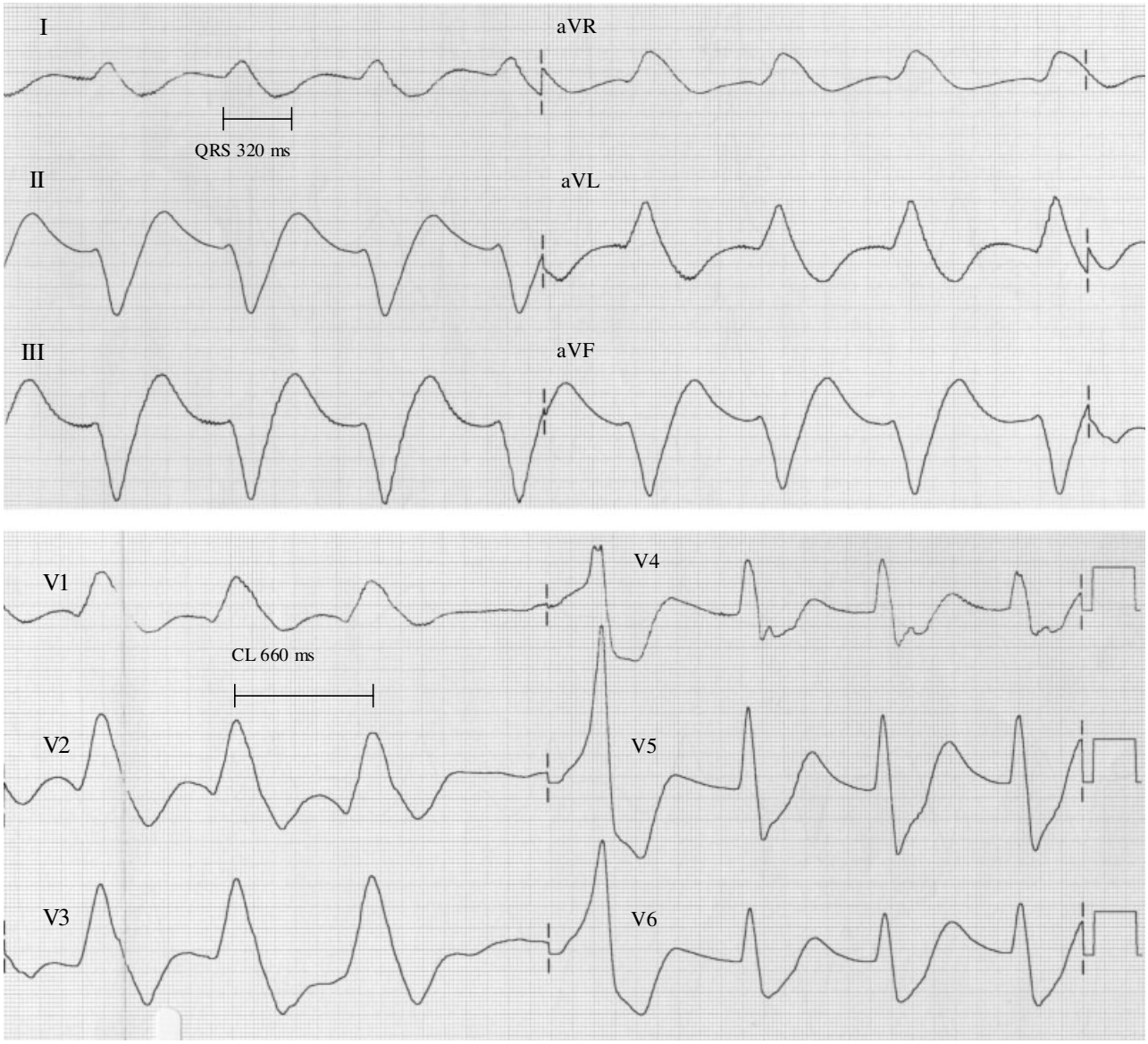

Fig. 1. Junctional tachycardia with aberrant intraventricular conduction. The 12-lead ECG shows a junctional tachycardia of rate 90/min, cycle length (CL) 660 ms. The duration of QRS complexes was 320 ms. The strip was registered 3.5 hour after the admission.

intraventricular conduction occured (Fig. 1). Within the next 30 minutes intermittent sinus beats with PR interval 360 ms, duration of QRS complexes 260 ms, and qR waves in aVR, V1 and V2 precordial leads appeared. Hypotension persisted and diuresis was missing but weak pupilar reflex was detected. In 4.5 hours after the admission brief attacks of ventricular tachycardia and episodes of slower junctional rhythm of rate 50/min without a need of defibrillation or introduction of temporary pacing were again registered. Pharmacological therapy consisted of volume load, naloxone, dopamine, correction of acidosis with natrium bicarbonate, atropine, lidocaine, mexiletine and intermitently isoprenaline administration. Restoration of sinus rhythm was observed 7 hours after the admission. At that time patient began to breathe spontaneously and tried to communicate so the endotracheal canule was removed. Despite of the still low blood pressure 75/50 mmHg diuresis occured. During the next 4 hours the neurological and psychical status continuously improved and normal blood pressure established. The control neurological examination 12 hours after the admission revealed the signs of a diffuse lesion of the nervous system and enhanced neuromuscular irritability. Topic lesions of the nervous system were not observed. Psychiatric evaluation has shown a post-conflict reactive state without residual suicidal tendencies or psychosis. Chest X-ray and echocardiography performed within 36 hours of hospital stay were normal. Retrograde amnesia did not allow us to exactly verify the number of ingested pills of propafenone but the number was estimated after consultation with his relatives based on missing remedies.

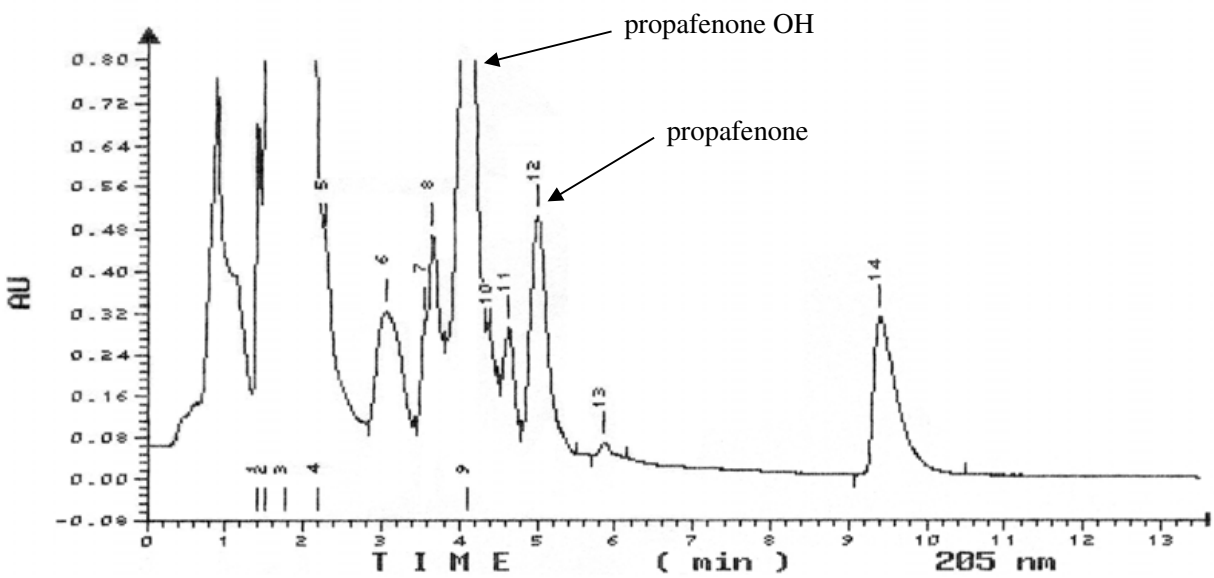

Fig. 2. Results of clinical toxicology from HPLC-REMEDi HS system. Semiquantitative analysis of an urine sample, taken 60 minutes after the admission by high performance liquid chromatography has shown overrange peak for propafenone 5-hydroxide, a metabolite of propafenone.

Laboratory findings

Immediately after the admission normal values of blood count and moderate combined respiratory and metabolic acidosis with hyperkapnia, hypoxemia, and deficiency of bases (pH 7.280; pCO_2 5.21; pO_2 4.65; BE -8.2) were detected. During the next hours marked leukocytosis (20.10^{-9} l), and moderate basophilia, eosinophilia and lymphopenia were found. Values of prothrombine, INR, fibrinogen, bilirubine, cholesterol, triacylglycerols, serum proteins and T-troponine were within normal limits. Elevated levels of creatinine (168.7 µmol/l, aspartate aminotransferase 2.39 µkat/l, alanine aminotransefrase 1.1 µkat/l, creatinkinase 56.8 µkat/l, amylase 9.69 µkat/l and serum myoglobine 3000 ng/l were found 12 hours after admission. Results of clinical toxicology were obtained by HPLC-REMEDi HS system based on high performance liquid chromatography (BIO-RAD, Hercules, Ca., USA) from the urine sample taken 60 minutes after admission. Semiquantitative analysis has shown high peaks for propafenone 5-hydroxide (Fig. 2). Entry level of ethanol was 0.24 %.

Discussion

Propafenone has been widely used in clinical practice in recent years. As a class IC antiarrhythmic agent it may show a significant proarrhythmogenic effect even at therapeutic doses. Relatively infrequent are haematologic reactions, as agranulocytosis (2), gastrointestinal and hepatic (3, 4), or neurological, as convulsions (5), amnesia (6, 7, 8), peripheral neuropathy (9), or exacerbation of myasthenia (10). Toxic effects of high doses including fatal outcome have been sporadically described in the literature (11 – 16). Fatal course is usually associated with cardiac conduction abnormalities with progression to asystole or electromechanical dissociation. Since a specific treatment is not available and resuscitation techniques may be of limited value, early diagnosis and primary detoxication are essential (17). Our case shows that in a structurally normal heart even massive over dose of propafenone may lead to manageable ventricular arrhythmias while the suppression of the sinoatrial activity may be followed by occurence of faster, but still stable junctional rhythm. Administration of alkalization solutions might be helpful, as far as they could facilitate the cell membrane hyperpolarization and/or displace tissue receptor sites by an increase in the nonionized fraction (18). The clinical course showed that the maximum of cardiac effects peaked 3.5 hours after ingestion of the drug and in less than 9 hours the majority of cardiac effects began to cease. Elevated levels of trasaminases, myoglobine and creatinine were in our opinion rather the consequence of global hypoxia due to hypoventilation and hypotension than a direct toxic effect of propafenone.

Severe propafenone self-intoxication was successfully treated in 28 year old man. The main clinical findings included coma, hypotension, acidosis, sinoatrial block, junctional tachycardia and ventricular arrhythmias necessitating defibrillation. Maximum occurence of arrhythmias was observed 2.5 hours after the admission in to the hospital, while the cessation of toxic signs started 4.5 hours later. Gastric lavage, arteficial ventilation, administration of alkalinization solutions and management of rhythm disorders were the most important therapeutic measures in this case. Semiquantitative analysis of urine sample by high performance liquid chromatography was helpful in confirmation of the toxic agent.

References

1. Capucci A, Boriani G. Propafenone in the treatment of cardiac arrhythmias. A risk-benefit appraisal. Drug Safety 12; 1995: 55—72.

2. Miwa LJ, Jolson HM. Propafenone associated agranulocytosis. Pacing Clin. Electrophysiol 1992; 15 (1): 387—390.

3. Mondardini A, Pasquino P, Bernardi P et al. Propafenone-induced liver injury: report of a case and review of the literature. Gastroenterology 1993; 104: 1524—1526.

4. Spinler SA, Elder CA, Kindwall KE. Propafenone-induced liver injury. Ann Pharmacother 1992; 26: 926—928.

5. Duvelleroy-Hommet C, Jonville-Bera AP, Autret A, Saudeau D, Autret E, Fauchier JP. Une crise convulsive chez un patient traite par propafenone et ketoconazole. Therapie 1995; 50: 164—165.

6. Jones RJ, Brace SR, Vander-Tuin EL. Probable propafenone-induced transient global amnesia. Ann Pharmacother 1995; 29: 586—590.

7. Chua TP, Farrell T, Lipkin DP. Myoclonus associated with propafenone. Brit Med J 1994; 308: 113.

8. Rambourg-Schepens MO, Grossenbacher F, Buffet M, Lamiable D. Recurrent convulsions and cardiac conduction disturbances after propafenone overdose. Vet Hum Toxicol 1999; 41: 153—154.

9. Galasso PJ, Stanton MS, Vogel H. Propafenone-induced peripheral neuropathy. Mayo Clin Proc 1995; 70: 469—472.

10. Lecky BR, Weir D, Chong E. Exacerbation of myasthenia by propafenone. J Neurol Neurosurg Psychiat 1991; 54: 377.

11. Picciotto G, Siragusa V, Cellura M, Ventimiglia C, Rotolo L. Intossicazione acuta da propafenone. Descrizione di un caso. Minerva Cardioangiol 1990; 38: 555—558.

12. Kerns W Jr, English B, Ford M. Propafenone overdose. Ann Emerg Med 1994; 24: 98—103.

13. Ielasi G, Panagia M, Grasso L, Caminiti G. Intossicazione volontaria acuta da propafenone. Caso clinico. Minerva Anestesiol 1993; 59: 69—73.

14. Lanari A, Brun M, Dormi A et al. Intossicazione da propafenone e verapamil. Descrizione di due casi clinici. Clin Terap 1994; 145: 457—461.

15. Maxeiner H, Klug E. Lethal suicidal intoxication with propafenone, after a history of self-inflicted injuries. Forensic Sci Int 1997; 89: 27—32.

16. Fonck K, Haenebalcke C, Hemeryck A et al. ECG changes and plasma concentrations of propafenone and its metabolites in a case of severe poisoning. J Toxicol Clin Toxicol 1998; 36: 247—251.

17. Koppel C, Oberdisse U, Heinemeyer G. Clinical course and outcome in class IC antiarrhythmic overdose. J Toxicol Clin Toxicol 1990; 28: 433—444.

18. Scanu P, Grollier G, Guilleman D et al. Malignant ventricular tachycardia during propafenone treatment in a child with junctional automatic tachycardia: effectiveness of intravenous molar sodium lactate. Pacing Clin Electrophysiol 1991; 14 (1): 783—786.

Received November 23, 2003.
Accepted December 12, 2003.